

7th EUROPEAN DIROFILARIA AND ANGIOSTRONGYLUS DAYS



 EUROPEAN SOCIETY OF
DIROFILARIOSIS AND
ANGIOSTRONGYLOSIS


MADRID
SEPTEMBER 23-24, 2022

PROCEEDINGS

7th **EDAD** Days

Madrid, Spain

September 22-24, 2022



Edited by:

© Morchón R., Carretón E., Montoya-Alonso J. A.

ISBN: 978-84-09-42834-2

Salamanca, Spain, 2022

ESDA official website:

<http://www.esda.vet/>

email: info@esda.vet

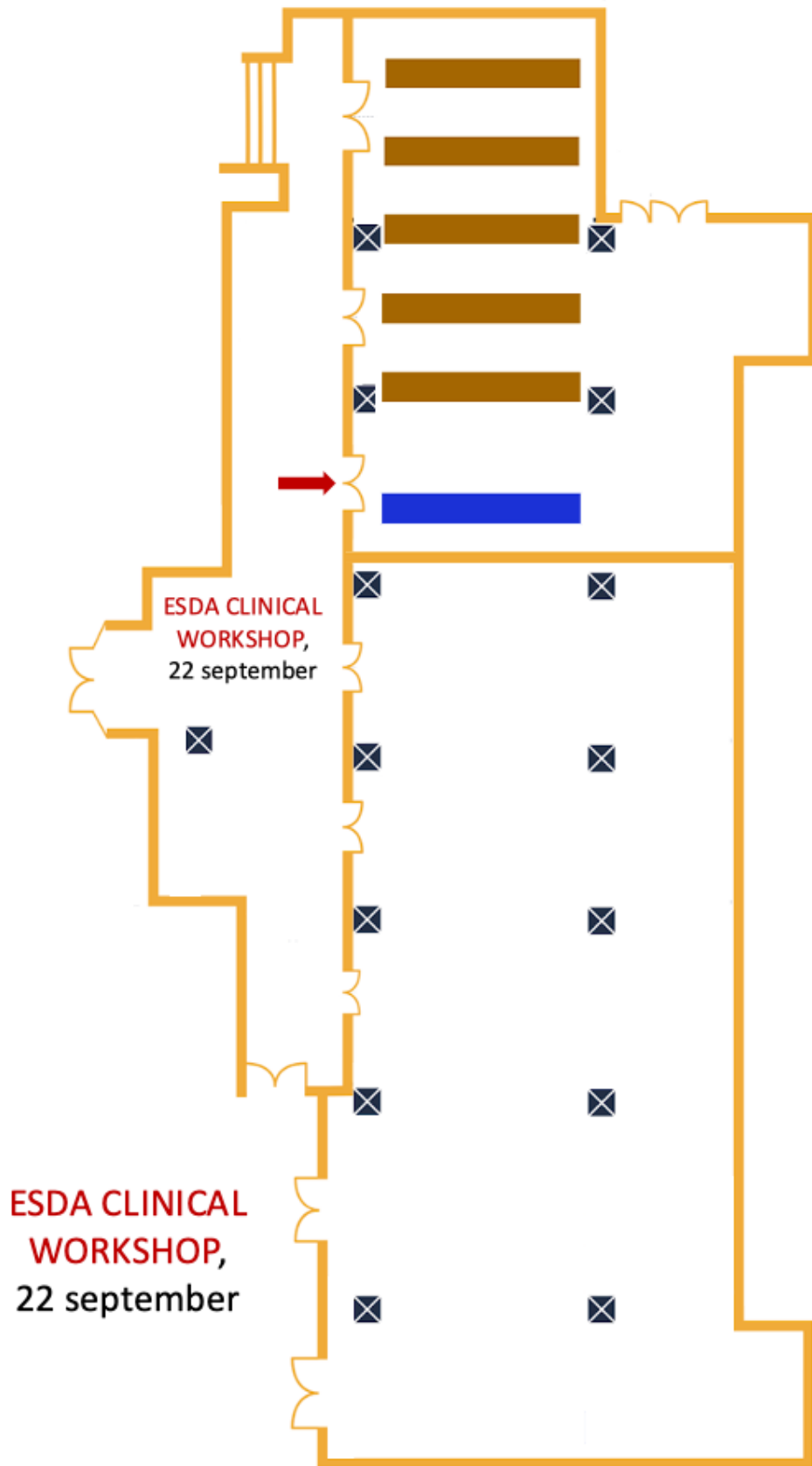
7th EDAD 2022 official website:

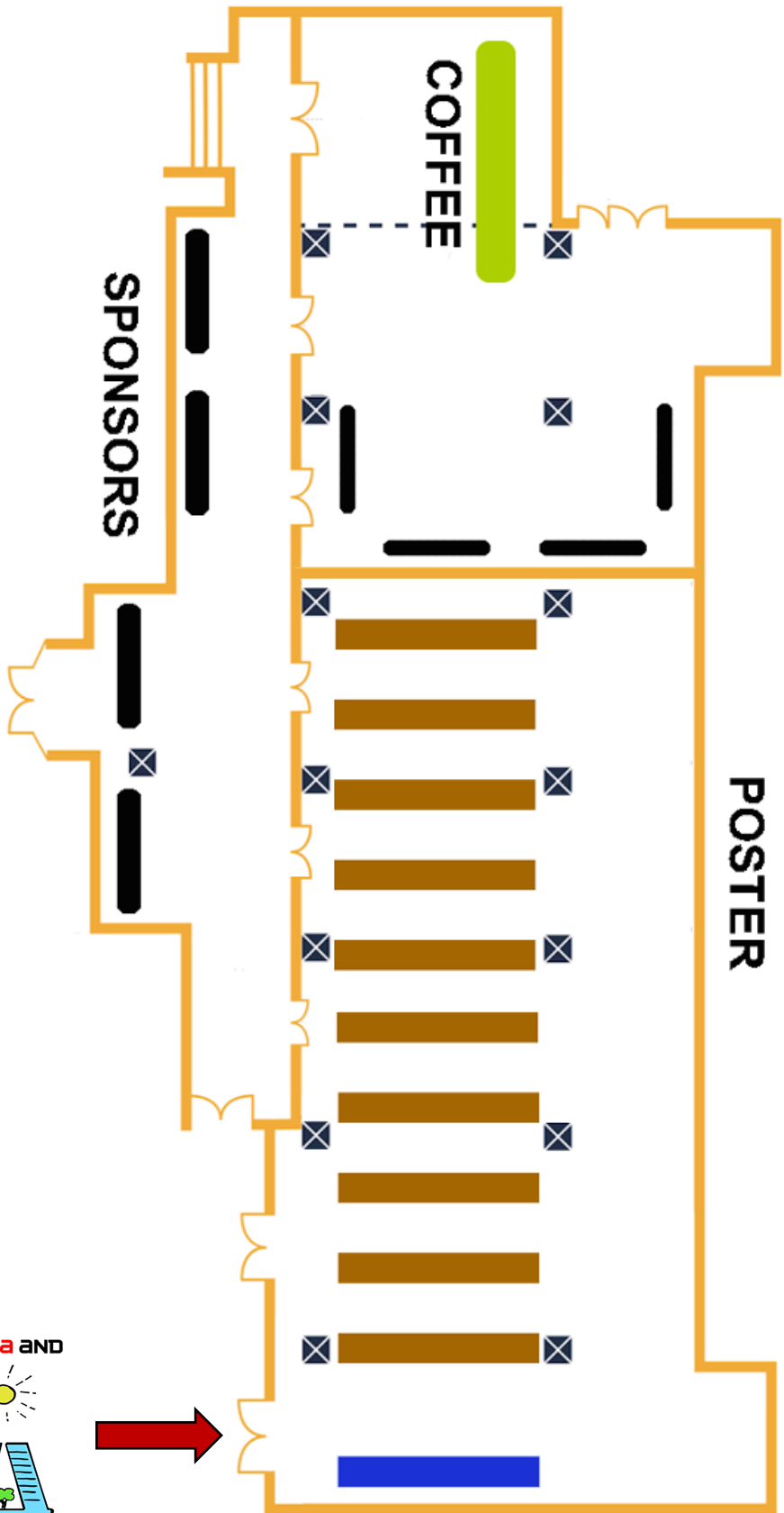
<http://www.esda.vet/index.php/esda-congress-2022>

The 7th European *Dirofilaria* and *Angiostrongylus* Days are organized under the patronage of:



VENUE





7th EUROPEAN DIROFILARIA AND ANGIOSTRONGYLUS Days



EUROPEAN SOCIETY OF DIROFILARIOSIS AND ANGIOSTRONGYLUS **MADRID** SEPTEMBER 23-24, 2022




CONTENTS

SPONSORS AND PARTNERS.....	1
COMMITTEES.....	2
GREETINGS FROM THE ORGANIZING COMMITTEE.....	3
ESDA CLINICAL WORKSHOP.....	4
SCIENTIFIC PROGRAMME 7 th EDAD Days.....	5
PLACE FOR LUNCH.....	10
INVITED SPEAKERS.....	11
ABSTRACTS	

7th EUROPEAN CONGRESS AND
PHARMACEUTICAL DAYS **TITLE AND SPEAKERS**

 Plenary presentations.....	19
 Oral communications.....	21
 Posters.....	23

7th EUROPEAN CONGRESS AND
PHARMACEUTICAL DAYS **ABSTRACTS**

 Plenary presentations.....	25
 Oral communications.....	52
 Posters.....	74



SPONSORS

GOLD



MSD
Animal Health



**Boehringer
Ingelheim**

SILVER



PARTNERS

SECRETARIAT



Paseo Chil, 313, 35006 Las Palmas de Gran
Canaria, Las Palmas, Spain

☎ 0034 693 942 795

Georgina Rouhana

georgina@laplazatours.com

<https://www.laplazatours.com/>

VENUE



Calle de López de Hoyos, 143,
28002 Madrid, Spain

☎ 0034 91 744 50 00

Lorena Castillo Asensio

lcastilloa@ilunionhotels.com

<https://www.il unionsuitesmadrid.com/>





COMMITTEES

7th EDAD 2022 ORGANIZING COMMITTEE

President:

Elena Carretón Gómez 

Secretary:

Rodrigo Morchón García 

Members:

Alberto Montoya 

Luigi Venco 

Ljubomir Curcin 

Anastasia Diakou 

Collaborators:

Iván Rodríguez Escolar 


Sara N. García Rodríguez 

Jorge I. Matos Rivero 

Noelia Costa Rodríguez 

7th EDAD 2022 SCIENTIFIC COMMITTEE


President:

Rodrigo Morchón García 

Members:

Elena Carretón Gómez 


Ljubomir Curcin 


Alberto Montoya Alonso 

Luigi Venco 

Anastasia Diakou 

Marco Genchi 

Angela Ionică 

Hans-Peter Fuehrer 

European *DIROFILARIA AND ANGIOSTRONGYLUS* Society (ESDA) Board

President:

Elena Carretón Gómez 

Vice-President:

Ljubomir Curcin 

Secretary:

Rodrigo Morchón García 

Treasurer:

Laura H. Kramer 





GREETINGS FROM THE ORGANIZING COMMITTEE

Dear colleagues,

As the Organizing Committee of the ESDA, it is a pleasure for us to present the 7th European *Dirofilaria* and *Angiostrongylus* Days of our society that will take place in September 2022 at the ILUNION Suites Madrid.

The 7th ESDA Days want to be a benchmark and offer the state-of-the art in Dirofilariosis and Angiostrongylosis, from a multidisciplinary point of view in a forum that brings together veterinarians, physicians and parasitologists.

We want to have your active participation and have the perspective of the industry as a fundamental axis in the field of *Dirofilaria* and *Angiostrongylus*. The 7th ESDA Days are a starting point ideal meeting to establish synergies with the different actors that we are involved in.

We are convinced that during these conferences we will be able to share experiences, get to know initiatives, establish links that allow us to achieve new objectives and research, but above all to work, in a multidisciplinary manner, with all the professionals and areas of knowledge to enhance our frontiers, advance in the knowledge of these parasites and reach safer practices for diagnosis, treatment and prevention in pets and humans.

Our Board has faced with great enthusiasm the challenge of improving day by day our Society with the support of all of you and we have transferred it to a Congress that marks a before and after from the point of view of quality and continuous improvement. The emergence of COVID-19 as a global pandemic has changed the world in many ways and all the scientific community has adapted to the current situation. This congress will be available as a hybrid format, both on-site and on-line, which will allow the participation of those professionals who have difficulties to come to Madrid. Also, as a show of solidarity, we offer free registration to Ukrainian professionals.

On behalf of the Board, we hope to be able to share these days with you.

Warm greetings.

The Organizing Committee.





ESDA CLINICAL WORKSHOP

This Pre-Congress Clinical Session is aimed at veterinarians, of an eminently practical nature, which will be lectured in Spanish.

THURSDAY, SEPTEMBER 22

16:30-17:00 **Check-in / Bienvenida**

17:00-17:15 Bravecto plus: una protección única como los gatos – Javier Godino (MSD Animal Health, Spain)

17:15–18:00 Epidemiología de dirofilariosis canina y felina en España: ¿hay filaria en mi clínica? La realidad de una enfermedad en expansión – Rodrigo Morchón (Salamanca, Spain)

18:00–18:45 ¿Lo estoy haciendo bien?: Dudas frecuentes durante el manejo de la dirofilariosis - Elena Carretón (Las Palmas de Gran Canaria, Spain)

18:45–19:15 Dirofilariosis felina: ¿es asma? – Laín García Guasch (Barcelona, Spain)

19:15–19:45 Efecto de *Dirofilaria immitis* en el endotelio vascular y sus consecuencias en nuestros pacientes - Rodrigo Morchón (Salamanca, Spain)

19:45–20:15 ¿Y tú qué harías...? Algunos casos clínicos – Elena Carretón (Las Palmas de Gran Canaria, Spain)

20:15-20:45 **Debate con café**

Sponsored by MSD Animal Health





SCIENTIFIC PROGRAM 7th EDAD DAYS

FRIDAY, SEPTEMBER 23

08:00-09:00 **Registration /Check-in**

Session 1: Epidemiology and Vectors

⇒ Chair: Elena Carretón (Spain)

09:00-09:20 Heartworm pandemic? Epidemiology of *Dirofilaria immitis* in Europe – Rodrigo Morchón (Spain)

09:20-09:40 New distribution trends of vectors in Europe – Hans-Peter Fuehrer (Austria)

09:40-09:50 *Dirofilaria immitis* is not a northern Italy parasite anymore - Ettore Napoli (Italy)

09:50-10:00 Haplotypes of *Dirofilaria repens* from Poland and selected countries of Central, North-Eastern Europe and the Middle East, an evaluation on the relation between the genetic diversity and the geographic distribution – Mustafa Alsarraf (Poland)

10:00-10:20

Sponsored by



myVBDmap: the real time way to map CVBDs - Marie Valourd (France)

10:20-10:30 Analysis through ecological niche modelling of the current risk of dirofilariasis transmission in the Iberian Peninsula (Spain and Portugal), and its future projection under climate change scenarios – Iván Rodríguez Escolar (Spain)

10:30-10:40 Survey on *D. immitis* and *D. repens* by Italian vets. Second Edition – Marco Genchi (Italy)

10:40-11:15 **Coffee Break**

Session 2: One health and Parasite/Host interaction

⇒ Chair: Anastasia Diakou (Greece)

11:15-11:35 The female side of *D. repens*. Is it breast cancer or not? – Elisabetta Scoccia (Italy)

11:35-11:55 Human angiostrongylosis in Europe – Claudia Paredes (Spain)

11:55-12:05 Spreading of *Dirofilaria immitis* in southern Italy: a threat to human and Animal Health – Simona Gabrielli (Italy)

12:05-12:15 Vector-borne parasites *Dirofilaria repens* and *Babesia canis*: hematological parameters and profile of immune response in naturally infected and co-infected dogs - Dagmara Wężyk (Poland)





- 12:15-12:35 Heartworm in ferrets, the great forgotten – Andrés Montesinos (Spain)
- 12:35-12:45 Angiogenic process as a survival mechanism produced by excretory/secretory antigens of *D. immitis* adult worms – Rodrigo Morchón (Spain)
- 12:45-12:55 *Dirofilaria repens* somatic antigen reduces the inflammatory cytokines in human dendritic cells and induces Th2 immune response in naïve CD4 t cells. Anna Zawistowska-Deniziak (Poland)
- 13:00-14:30 **Lunch time**

Session 3: New advances in diagnosis

⇒ Chair: Hans-Peter Fuehrer (Austria)

- 14:30-14:50 The role of ultrasounds for the diagnosis of *D. immitis* and *D. repens* infection in dogs – Luigi Venco (Italy)
- 14:50-15:10 New biomarkers in heartworm disease – Elena Carretón (Spain)
- 15:10-15:20 Right pulmonary artery distensibility index in heartworm infected dogs: are the different methods leading to same results? – Angelo Basile (Italy)
- 15:20-15:30 Evaluation of thoracic computed tomography findings in dogs naturally infected by *Dirofilaria immitis* – Jorge I. Matos (Spain)
- 15:30-15:50 Can we diagnose *Dirofilaria repens*? – Marco Genchi (Italy)
- 15:50-16:00 The antigens positive and Knott negative dog. Should I treat or should I no? – Luigi Venco (Italy)
- 16:00-16:10 Cortisol in canine heartworm before and after adulticide treatment - Noelia Costa (Spain)
- 16:10-16:20 A new complex diagnostic approach for detection of *Dirofilaria repens* infections - Mateusz Pękacz (Poland)
- 16:20-16:50 **Coffee Break**


Session 4: Feline heartworm: the silent disease

⇒ Chair: Ljubomir Curcin (Serbia)

- 16:50-17:10 Is it HARD? Management of Heartworm Associated Respiratory Distress in cats – Lain García Guasch (Spain)






- 17:10-17:30 Update and trends in feline epidemiology – Elena Carretón (Spain)
- 17:30-17:40 Clinical characteristics of heartworm infected cats in the Canary Islands – Sara García Rodríguez (Spain)
- 17:40-18:00
Sponsored by
 Combination of fluralaner and moxidectin to protect cats from heartworm infections for 12 weeks – Jason Drake (USA)
- 18:00-18:20 Diagnosis and treatment of feline heartworm: What is new? – Luigi Venco (Italy)

SATURDAY, SEPTEMBER 24

08:30-09:00 **Registration /Check-in**

Session 5: Clinical pathology, heartworm management and prevention (I)

⇒ Chair: Rodrigo Morchón (Spain)


- 09:00-09:20 Heartworm management in non-endemic and new endemic areas - Ljubomir Curcin (Serbia)
- 09:20-09:40 Heartworm management and prevention. A review: assessment of rapid immunochromatographic test and selamectin topical route - Ahmed Addali Alvarez (Spain)
Sponsored by

- 09:40-09:50 Nonbacterial thrombotic endocarditis of the tricuspid valve in a male dog with dirofilariasis- Case report – Elena Vulcan (Romania)
- 09:50-10:00 Assessment of TTE (transthoracic echocardiography) guidance during caval syndrome surgery – Leca Florin (Romania)
- 10:00-10:20 Is it terminal? Medical treatment of caval syndrome - Todor Kalinov (Bulgaria)
- 10:20-10:40 Evolution of the control of *Dirofilaria immitis* infections, during my lifetime– Jorge Guerrero (Perú)
- 10:40-11:15 **Coffee Break**
-





Session 6: Clinical pathology, heartworm management and prevention (II)

⇒ Chair: Luigi Venco (Italy)

- 11:15-11:35 Loss of efficacy (LOE)/Resistance in Europe: is it happening? – Anastasia Diakou (Greece)
- 11:35-11:55 Evaluation of the adulticidal efficacy based on different formulations of moxidectin combined with doxycycline in dogs with heartworm disease – Lavinia Ciuca (Romania)
- 11:55-12:15
Sponsored by
 Safety of oral afoxolaner formulated with or without milbemycin oxime in homozygous MDR1 deficient collie dogs – Loic Antoine (France)
- 12:15-12:25 Liver assessment of dogs naturally infected by *Dirofilaria immitis* – Bruno Alberigi (Brazil)
- 12:15-12:25 Effect of MOXY-DOXY treatment on the lungs of dogs naturally infected with *Dirofilaria immitis* – Bruno Alberigi (Brazil)
- 12:35-12:55 Epidemiology and therapy related problems in South America - Norma Labarthe (Brazil)
- 13:00-14:30 **Lunch time**

Session 7: Angio Forum

⇒ Chair: Marco Genchi (Italy)

- 14:30-14:50 Current distribution and expansion of angiostrongylosis in Europe – Andreas Oehm (Switzerland)
- 14:50-15:10 Neurological and neuroradiological aspects of dogs affected by *Angiostrongylus vasorum* - Lorenzo Golini (Switzerland)
- 15:10-15:20 Angiostrongylosis in the United Kingdom. clinical characteristics of an increasingly frequent pathology: description of 5 cases – Yaiza Falcón (United Kingdom)
- 15:20-15:30 Atypical intraocular migration of *Angiostrongylus vasorum* – Iulia-Elena Filipescu (Italy)
- 15:30-15:50 Advances in the pathogenesis of canine angiostrongylosis – Andreas Oehm (Switzerland)





15:50-16:00 Antigenal evaluation of dirofilariasis and angiostrongylosis in dogs from northern and central Portugal – Joana Guimarães (Portugal)


16:00-16:30 **Coffee Break**

Session 8: Final Remarks

16:30-16:50 Heartworm disease. Not just a health topic for cats and dogs. How to better manage and optimize earnings and customer management – Renato Costa (Brazil)

16:50-17:10 **Closing Remarks (round table)**

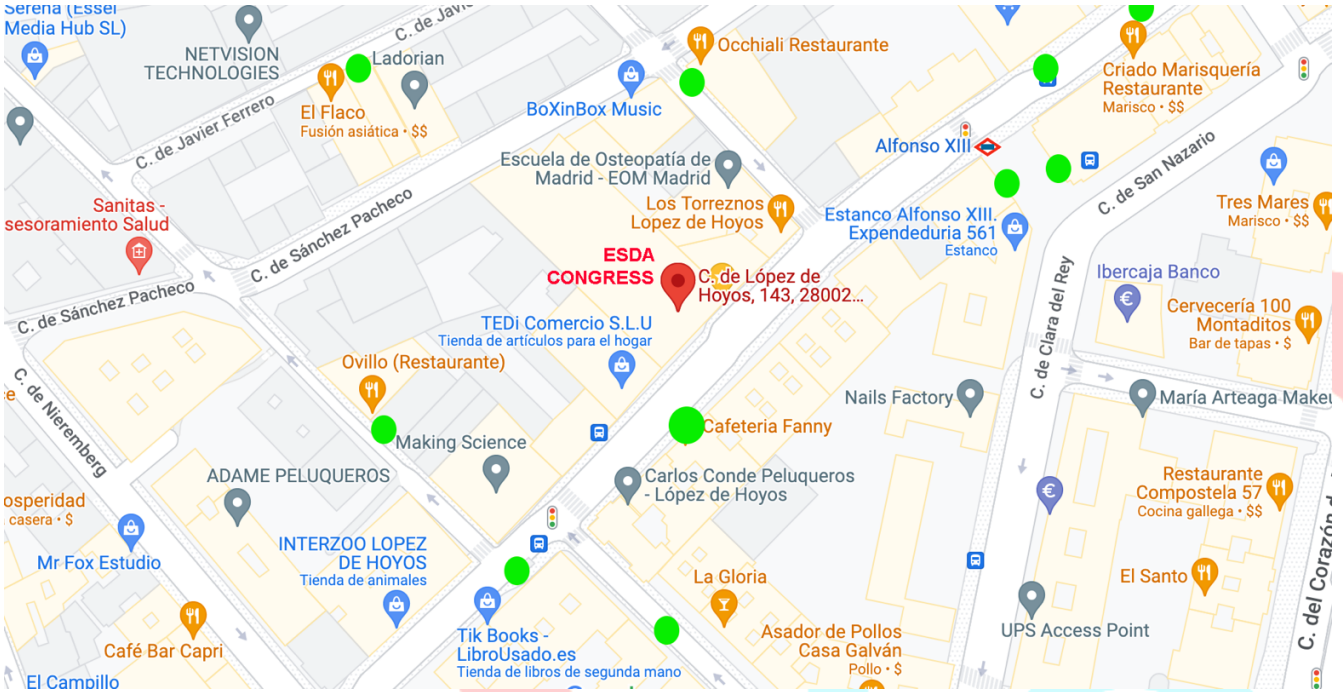
17:10-18:00 **General Assembly**

21:00 **Gala Dinner.** Sponsored by  EUROPEAN SOCIETY OF
DIROFILARIOSIS AND
ANGIOSTRONGYLUS





PLACE FOR LUNCH



- [Restaurants and bars for lunch.](#)
- [ESDA congress.](#)





INVITED SPEAKERS

Ahmed Addali Alvarez, MBA, Global Medical & Marketing Manager, Companion Animals at Virbac (Spain)



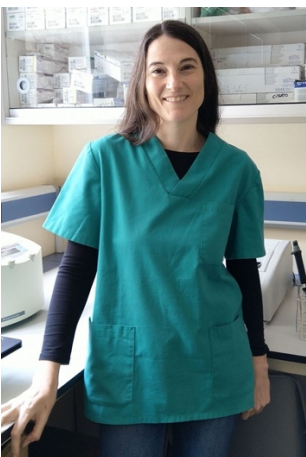Graduated in Veterinary Medicine at Leon University, Spain. MBA São Paulo, Brazil. Postgraduate degree at Adventist University São Paulo, Brazil. More than 20 years' experience in three of the largest veterinary pharmaceutical companies in Spain and Brazil being responsible for Companion Animals' Medical, Marketing, Commercial and Business Units. Specialist in parasitides market, molecules, and products.

Loic Antoine, PhD, Global Technical manager, Boehringer Ingelheim Animal Health (France)



French veterinarian who has been working in USA, France and Austria for the past 10 years. He is now a member of the Boehringer-Ingelheim technical services in Lyon and he dedicates most of his time to parasites and parasiticides.

Elena Carretón, DVM, MSc, PhD, University of Las Palmas de Gran Canaria (Spain)



Doctor Europeus in Veterinary Medicine from the University of Las Palmas de Gran Canaria receiving the Extraordinary Doctorate Award. She is currently Associate Professor of Veterinary Medicine at the University of Las Palmas de Gran Canaria in Spain. She has co-authored approximately 70 articles in peer-reviewed journals, and several books and book chapters on heartworm, as well as more than 200 communications and conferences in national and international congresses. Her scientific career is focused on the study of the pathology and epidemiology of *Dirofilaria immitis* in animals, as well as its zoonotic aspects and implications on human health. She has received several national awards for her work in scientific outreach.





Lavinia Ciuca, DVM, PhD, resident EVPC (Romania)



Dr. Ciuca received her veterinary degree from the University of Agricultural Sciences and Veterinary Medicine of Iasi, Romania, in 2012 and a PhD in veterinary sciences from the same university in 2016. The main subject of the PhD thesis was on *Dirofilaria* in dogs and humans. In the present, she is resident in the second year of European Veterinary Parasitology College at the Department of Veterinary Medicine and Animal Production, University of Naples Federico II, Italy. Dr. Ciuca has participated in several research projects with the focus on epidemiology and diagnosis of the main parasitic diseases in dogs and cats and she is author and co-author of several scientific publications in national and international journals.

Renato Costa, DVM, MSc, Diretor Regional Pet Care S/A (Brazil)



Awarded a Masters' degree in Small Animal Clinical Sciences focused on Canine Dirofilariasis at UFRRJ, Brazil in 2001, Renato founded Animália Veterinary Hospital in 1993 in Rio de Janeiro where he works as Manager, General Practitioner and Surgeon. Currently is the Technical Director of the Brazilian Small Animal Veterinary Hospital Association (ABHV).

Ljubomir Curcin, DVM spec, Veterinary clinic Intervet, Belgrade (Serbia)



He graduated in 1999 at the Faculty of Veterinary Medicine in Belgrade, Serbia. He has worked as a small animal clinician for more than twenty years. His fields of interest are diagnostic imaging, surgery and vector-borne diseases in dogs and cats. He is co-author of more than 30 papers.





Anastasia Diakou, DVM, PhD, full Professor, Laboratory of Parasitology and Parasitic Diseases, School of Veterinary Medicine, Faculty of Health Sciences, Aristotle University of Thessaloniki (Greece).



Dr. Diakou holds an academic position since 2001. To date she has (co-)/authored 124 publications and participated with 141 presentations in 86 scientific congresses. Her main scientific interests are the parasites and parasitic diseases of dogs, cats and wildlife, and their implications to public health.

Jason Drake, DVM, DACVM-Parasitology, Director, Scientific Marketing Affairs, Global Companion Animal Parasitides, Merck Animal Health (USA)



Dr. Drake earned his DVM from Texas A&M University. He practiced small animal medicine in Washington State, and joined Novartis Animal Health in 2000, serving as the Professional Services Veterinarian for the southeastern USA. Dr. Drake has held a number of different technical and marketing roles within the animal health industry, and currently provides technical support to the Merck Global Companion Animal Parasiticides marketing team, supporting both existing and pipeline products. Dr. Drake has co-authored more than 30 peer-reviewed parasitology-related manuscripts and earned his Diplomate of the American College of Veterinary Microbiology (Parasitology) in 2016. Dr. Drake is a veteran of the United States Army Veterinary Corps and has deployed to southwest Asia with a mission that included food safety and military working dog veterinary care. His recent projects have included evaluating the changing prevalence of heartworm and gastrointestinal nematode infections in dogs.

Hans-Peter Fuehrer, PhD, University of Vienna (Austria)



Hans-Peter Fuehrer is parasitologist and leader of the vector and vector-borne pathogens group at the Institute of Parasitology at the Vetmeduni Vienna, Austria. His main research focus is set on mosquitoes and mosquito-borne pathogens incl. *Dirofilaria immitis* and *D. repens*.





Láin García Guasch, DVM, MSc, PhD, Acred. AVEPA (Spain)



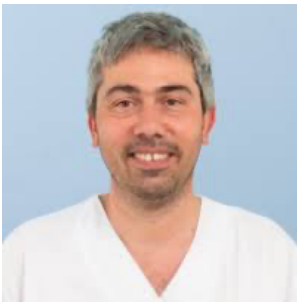Graduated in Veterinary Medicine at the Autonomous University of Barcelona in 1998, and PhD in Veterinary Medicine at the University of Las Palmas de Gran Canaria in 2009. Member of the Cardiology and Respiratory Service of the Hospital Veterinari Molins IVC Evidensia. Head of the Cardiology Service at Hospital Veterinaria del Mar IVC Evidensia. Research member of the Veterinary Medicine and Therapeutic Research Service at the University Institute for Research in Biomedical and Health Sciences of the ULPGC. AVEPA accredited in Cardiology since February 2012. Teacher of postgraduate courses and author of internationally peer-reviewed articles. He is also author of several books within the specialty of cardiology and respiratory in small animals.

Marco Genchi, DVM, PhD, University of Parma (Italy)



Associate Professor of Parasitology and Parasitic Diseases, University of Parma. Research topics include epidemiology, pathogenesis, host-parasite relationships, and parasitology diagnosis. An important line of research is represented by studies on *Dirofilaria immitis* and *D. repens*. Author of over 120 publications in national and international journals, books and book chapters.

Lorenzo Golini, DVM, Faculty of Veterinary Medicine, University of Zurich (Switzerland)



Lorenzo Golini graduated in veterinary medicine with full marks in 2004, discussing a thesis on cognitive dysfunction in the senior dog. In 2006, he completes a master's degree in "clinic of behavioral diseases of the dog and cat," at the University of Torno. Meanwhile, he is involved in dog and cat medicine and surgery in several centers in Rome. Until 2008, he completes several externships at the neurology sections of the UPENN (Philadelphia, USA), Madison-Wisconsin (USA) and Georgia (USA) schools of veterinary medicine. In 2008, residency in neurology and neurosurgery at VetSuisse of the University of Zurich (CH) under the supervision of Prof. F. Steffen, DECVN. In 2014, obtains diplomas from the European College of Veterinary Neurology. Senior clinician at Zurich faculty until 2015, when he moved to UK to start neurology and neurosurgery service at NorthWest Surgeons Ltd private clinic. In August 2019, at the Veterinary Neurology and Neurosurgery service of the San Marco Veterinary Clinic and Laboratory, in Veggiano (PD). Since 2020, he is again at the Faculty of Veterinary Medicine, University of Zurich (Switzerland) He is the author of several international scientific publications, author of papers at national and international level in several conferences on veterinary neurology.



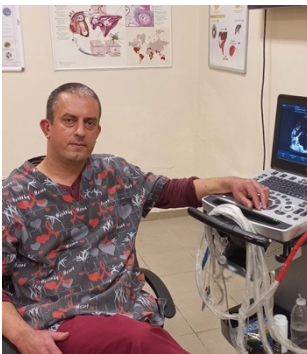

Jorge Guerrero, DVM, PhD, Latin American Veterinary Conference (LAVC) (Perú)



Certificate at the American College of Microbiology (ACVM) and retired from the European College of Veterinary Parasitology (EVPC). He has worked in research in the field of immunology and parasitic diseases in farm animals and small animals in Peru, Brazil, Spain and the United States. He has worked for 28 years in different areas of the global pharmaceutical industry, retiring as Executive Director of Veterinary Services for North America at Merck and Co, Inc in 2001. He served for 35 years as Adjunct Senior Professor at the University of Pennsylvania School of Veterinary Medicine. He has also served as a visiting professor in Spain, Italy, Brazil, Sweden, Germany, and Peru and is an Honorary Professor (Emeritus) at the Universidad Nacional Mayor de San Marcos de Lima. Until 2010 he has been Editor-in-Chief of the International Journal of Applied Research in Veterinary Medicine and Associate Editor of the American Heartworm Society, and Honorary Member of the latter in 2015. Board member since 2002 and President (2007-2008) of the North American Veterinary Community (NAVC). Among other awards, has received the 2005 American Association of Veterinary Parasitologists Top Research Award, the gold medal from the Association of Spanish Small Animal Veterinarians (AVEPA) in 2014 and the global award of merit from the World Association of Small Animal Veterinarians (WSAVA) in 2016. Dr. Guerrero has more than 188 publications in indexed journals, one published book, several book chapters, including one in the Merck Veterinary Manual, and a US patent. Currently, he is President and CEO of the Latin American Veterinary Conference (LAVC).

Todor Kalinov, DVM, Veterinary Clinic Vitalis, Plovdiv (Bulgaria)



Todor Kalinov was born on 22.09.1980 in Plovdiv, Bulgaria. He graduated in Veterinary Medicine in 2006 in Trakia University, Stara Zagora, Bulgaria. He works at the veterinary clinic Vitalis, Plovdiv. Todor is mainly interested in small animals cardiology and ultrasound diagnostic. He is a member of Bulgarian Association of Veterinary Cardiology and European Society of Veterinary Cardiology. He is keen on extreme sports – wakeboard and snowboard.

Norma Labarthe, DVM, PhD, Universidade Federal Fluminense (Brazil)



Veterinarian dedicated to small animal medicine, with special interest in arthropod-borne diseases and in biodiversity and health issues. Has published over 100 papers and mentored countless students. Works hard to put scientific knowledge in favor of pets' health and welfare. Spends many hours trekking or swimming while observing nature, trying to learn from it how to build a fair world for the future generations.



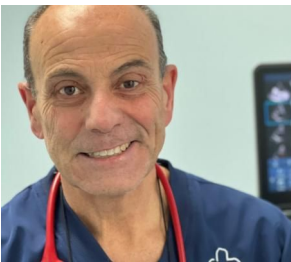

Andrés Montesinos, DVM, PhD, Hospital Veterinario Los Sauces, Madrid (Spain)



Andres Montesinos, graduated from the Veterinary Faculty of UCM Madrid in 1992. Since 1995 director of the Exotic Animal Hospital Los Sauces in Madrid fully dedicated to exotics medicine. Andres got his PhD in 2017 with a thesis about PK/PD of meloxicam in AGP. Master in veterinary science research and accredited in exotic pet medicine by the Spanish Association of Veterinarians. Since 2019 is also associate professor of Medicine and Surgery of exotics animal in the School of Veterinary of the Complutense University in Madrid. His areas interest are avian clinical pathology and pharmacology.

José Alberto Montoya-Alonso, DVM, MSc, Bi-PhD, University of Las Palmas de Gran Canaria (Spain)



Graduated and PhD in Veterinary Medicine at the Complutense University of Madrid. PhD in Medicine at the University of Las Palmas de Gran Canaria (ULPGC). University Specialist in Obesity, Specialist in Animal Welfare and Animal Health. Board Certified in Pediatric Internal Medicine and Cardiology animals and Master's Degree in Educational Innovation and Evaluation of Programs Training by the National Distance University. Professor of medicine and surgery animal of the Department of Animal Pathology, where he has been its director, in the Faculty of Veterinary of the ULPGC. Head of the Veterinary Medicine Service and the research group of Veterinary Clinic and therapeutic research of the Institute University of Biomedical and Health Research of the ULPGC. Coordinator of the Research Doctorate Program in Biomedicine. Numerary Elected Academician of the Royal Academy of Veterinary Sciences of Spain. Author and coauthor of almost 100 peer-reviewed articles. Author and coauthor of books and book chapters in cardiorespiratory medicine in small animals.

Rodrigo Morchón, PhD, Zoonotic Diseases and One Health research group, University of Salamanca (Spain)



Full Professor in the Parasitology Area and head of the research group on Zoonotic Diseases and One Health at the University of Salamanca (USAL). Degree in Biological Sciences and Doctor Europeus from USAL with Extraordinary Doctorate Award. He teaches different bachelor's and Master's degrees at USAL and other universities on topics related to animal and human parasitology, new technologies and teaching innovation, and other topics in the field of Health Sciences. His main line of research is the study of animal and human dirofilariosis (*Dirofilaria immitis* and *D. repens*) as well as other vector-borne zoonotic diseases and *Angiostrongylus vasorum*. Author and coauthor of over 150 publications in national and international journals, books and book chapters.





Andreas Oehm, DVM, PhD, Institute of Parasitology, University of Zurich (Switzerland)



Studied Veterinary Medicine, Ludwig-Maximilians-University, Munich; PhD in 2019, Dr. med. vet. in Veterinary Epidemiology, University of Munich. Since September 2021 is a researcher at the Veterinary Parasitology group, at the Institute of Parasitology, University of Zurich. Since April 2022, German Board Certification (FTA) in Epidemiology.

Claudia Paredes Esquivel, Senior lecturer, Laboratory of Zoology. Department of Biology, University of the Balearic Islands (Spain)



Senior lecturer at the University of the Balearic Islands in Spain. Claudia Paredes obtained a bachelor degree in Biological Sciences at the University of San Marcos Lima, Peru. In 2004, she joined the Liverpool School of Tropical Medicine (LSTM) as a PhD fellow. In 2019 she led a team that discovered *Angiostrongylus cantonensis* in Mallorca, the first European endemic foci. Now, her team is focused in understanding the molecular epidemiology of the parasite in this region.

Elisabetta Scoccia, MD. Maugeri Clinical-Scientific Institutes of Pavia (Italy)



Assistant Surgeon at the Operative Unit of Breast Surgery of the Maugeri Clinical-Scientific Institutes of Pavia, Eusoma certified Breast Unit. She has a Degree in Plastic Surgery and a II level Master in Breast Surgery and deals with Breast Oncology mainly in the field of Reconstructive Oncoplasty.

Marie Varlourd, MS, PhD, Global Technical Manager for Companion Animal, Ceva Santé Animale (France)



She is Global Technical Manager for Companion Animal parasitology in Ceva Santé Animale since 2012. Marie graduated as an engineer. Before starting her PhD she completed a research master focused on the molecular and cellular aspects of nutrition.





Luigi Venco, DVM, SCPA, EVPC Dipl, EBVS, European Veterinary Specialist in Parasitology (Italy)



Author of more than 50 papers on Internationally peer reviewed journals he is a Diplomate of the EVPC (European Veterinary Parasitology College) and Licensed University Professor of veterinary infectious and parasitic diseases. He works as consultant for Veterinary Hospitals in Italy and abroad in the fields of Internal medicine, Cardiology (clinical, interventional and surgical) and Clinical Parasitology.





ABSTRACTS

TITLE AND SPEAKERS



Plenary presentations

- I-1. HEARTWORM PANDEMIC? WHAT HAS HAPPENED TO HEARTWORM DISEASE IN EUROPE IN THE LAST 10 YEARS? Morchón, R.
- I-2. NEW DISTRIBUTION TRENDS OF VECTORS IN EUROPE. Fuehrer, H.P.
- I-3. MyVBDmap, THE REAL TIME WAY TO MAP CANINE VECTOR BORNE DISEASES. Varloud, M.
- I-4. THE FEMALE SIDE OF D. REPENS. IS IT A BREAST CANCER OR NOT? Scoccia, E.
- I-5. HUMAN ANGIOSTRONGYLIASIS IN EUROPE. Paredes-Esquivel, C.
- I-6. DIROFILARIASIS (HEARTWORM DISEASE) IN FERRETS. Montesinos, A.
- I-7. THE ROLE OF ULTRASOUNDS FOR THE DIAGNOSIS OF *D. IMMITIS* AND *D. REPENS* INFECTION IN DOGS. Venco, L.
- I-8. NEW BIOMARKERS IN HEARTWORM DISEASE. Carretón, E.
- I-9. CAN WE DIAGNOSE *DIROFILARIA REPENS*? Genchi, M.
- I-10. IS IT HARD? DIAGNOSIS AND MANAGEMENT OF FELINE HARD. García-Guasch, L.
- I-11. UPDATE AND TRENDS IN FELINE EPIDEMIOLOGY. Carretón, E.
- I-12. COMBINATION OF FLURALANER AND MOXIDECTIN TO PROTECT CATS FROM HEARTWORM INFECTIONS FOR 12 WEEKS. Drake, J.
- I-13. DIAGNOSIS AND TREATMENT OF FELINE HEARTWORM DISEASE. WHAT IS NEW? Venco, L.
- I-14. HEARTWORM MANAGMENT IN NON ENDEMIC AND NEW ENDEMIC AREAS. Curcin, Lj.
- I-15. HEARTWORM MANAGEMENT AND PREVENTION: A REVIEW: ASSESSMENT OF RAPID IMMUNOCHROMATOGRAPHIC TEST AND SELAMECTIN TOPICAL ROUTE - Addali Alvarez, A.
- I-16. IS IT TERMINAL? MEDICAL TREATMENT OF CAVAL SYNDROME. Kalinov, T.





I-17. EVOLUTION OF THE CONTROL OF *DIROFILARIA IMMITIS* INFECTIONS, DURING MY LIFETIME. Guerrero, J.

I-18. *DIROFILARIA IMMITIS* AND LOE/RESISTANCE IN EUROPE: IS IT HAPPENING? Diakou, A.

I-19. EVALUATION OF THE ADULTICIDAL EFFICACY BASED ON DIFFERENT FORMULATIONS OF MOXIDECTIN COMBINED WITH DOXYCYCLINE IN DOGS WITH HEARTWORM DISEASE. Ciucă L.

I-20. SAFETY OF ORAL AFOXOLANER FORMULATED WITH OR WITHOUT MILBEMYCIN OXIME IN HOMOZYGOUS MDR1 DEFICIENT COLLIE DOGS. Drag, M.

I-21. *DIROFILARIA IMMITIS* EPIDEMIOLOGY AND THERAPY RELATED PROBLEMS IN SOUTH AMERICA. Labarthe, N.

I-22. CURRENT DISTRIBUTION AND EXPANSION OF ANGIOSTRONGYLOSIS. Oehm, A.W.

I-23. NEUROLOGICAL AND NEURORADIOLOGICAL ASPECTS OF DOGS AFFECTED BY *ANGIOSTRONGYLUS VASORUM*. Golini, L.

I-24. ADVANCES IN THE PATHOGENESIS OF CANINE ANGIOSTRONGYLOSIS. Oehm, A.W.

I-25. HEARTWORM DISEASE. NOT JUST A HEALTH TOPIC FOR CATS AND DOGS. HOW TO BETTER MANAGE AND OPTIMIZE EARNINGS AND CUSTOMER MANAGEMENT. Costa, R.





Oral communications

- O-1. *DIROFILARIA IMMITIS* IS NOT A NORTHERN ITALY PARASITE ANYMORE.** Napoli, E.
- O-2. HAPLOTYPES OF *DIROFILARIA REPENS* FROM POLAND AND SELECTED COUNTRIES OF CENTRAL, NORTH-EASTERN EUROPE AND THE MIDDLE EAST, AN EVALUATION ON THE RELATION BETWEEN THE GENETIC DIVERSITY AND THE GEOGRAPHIC DISTRIBUTION.** Alsarraf, M.
- O-3. ANALYSIS THROUGH ECOLOGICAL NICHE MODELLING OF THE CURRENT RISK OF DIROFILARIASIS TRANSMISSION IN IBERIAN PENINSULA (SPAIN AND PORTUGAL), AND ITS FUTURE PROJECTION UNDER CLIMATE CHANGE SCENARIOS.** Rodríguez-Escolar, I.
- O-4. SURVEY OF ITALIAN VETERINARY PRACTITIONERS ON *DIROFILARIA IMMITIS* AND *D. REPENS*: SECOND EDITION.** Genchi, M.
- O-5. SPREADING OF *DIROFILARIA IMMITIS* IN SOUTHERN ITALY: A THREAT TO HUMAN AND ANIMAL HEALTH.** Gabrielli, S.
- O-6. Vector-borne parasites *Dirofilaria repens* and *Babesia canis*: hematological parameters and profile of immune response in naturally infected and co-infected dogs.** Weżyk, D.
- O-7. ANGIOGENIC PROCESS AS A SURVIVAL MECHANISM PRODUCED BY WITH EXCRETORY/SECRETORY ANTIGENS OF *DIROFILARIA IMMITIS* ADULTS WORMS AND CUTICLE PROTEINS.** Morchón, R.
- O-8. NONBACTERIAL THROMBOTIC ENDOCARDITIS OF THE TRICUSPID VALVE IN A MALE DOG WITH DIROFILARIASIS. CASE REPORT.** Vulcan, E.T.
- O-9. RIGHT PULMONARY ARTERY DISTENSIBILITY INDEX IN HW INFECTED DOGS: ARE THE DIFFERENT METHODS LEADING TO SAME RESULTS?** Basile, A.
- O-10. EVALUATION OF THORACIC COMPUTED TOMOGRAPHY FINDINGS IN DOGS NATURALLY INFECTED BY *DIROFILARIA IMMITIS*.** Matos, J.I.
- O-11. THE AG POSITIVE AND KNOTT NEGATIVE DOG: SHOULD I TREAT OR SHOULD I NOT?** Venco, L.
- O-12. MEASUREMENT OF CORTISOL IN DOGS INFECTED BY *DIROFILARIA IMMITIS*.** Costa-Rodríguez, N.
- O-13. CLINICAL AND RADIOLOGICAL FINDINGS IN CATS NATURALLY AFFECTED BY HEARTWORM ASSOCIATED RESPIRATORY DISEASE.** García-Rodríguez, S.N.
- O-14. ASSESSMENT OF TTE (TRANSTHORACIC ECHOCARDIOGRAPHY) GUIDANCE DURING CAVAL SYNDROME SURGERY.** Leca, F.





- O-15. LIVER ASSESSMENT OF DOGS NATURALLY INFECTED BY *DIROFILARIA IMMITIS*.** Alberigi, B
- O-16. EFFECT OF MOXY-DOXY TREATMENT ON THE LUNGS OF DOGS NATURALLY INFECTED WITH *DIROFILARIA IMMITIS*.** Alberigi, B.
- O-17. ANGIOSTRONGYLOSIS IN THE UNITED KINGDOM. CLINICAL CHARACTERISTICS OF AN INCREASINGLY FRECUENT PATHOLOGY: DESCRIPTION OF 5 CASES.** Falcon-Cordón, Y.
- O-18. ATYPICAL INTRAOCULAR MIGRATION OF *ANGIOSTRONGYLUS VASORUM*.** Filipescu, I.E.
- O-19. ANTIGENAL EVALUATION OF DIROFILARIASIS AND ANGIOSTRONGYLOSIS IN DOGS FROM NORTHERN AND CENTRAL PORTUGAL.** Esteves-Guimarães, J.
- O-20. A NEW COMPLEX DIAGNOSTIC APPROACH FOR DETECTION OF *DIROFILARIA REPENS* INFECTIONS.** Pełacz, M.
- O-21. DIROFILARIA REPENS SOMATIC ANTIGEN REDUCES THE INFLAMMATORY CYTOKINES IN HUMAN DENDRITIC CELLS AND INDUCES TH2 IMMUNE RESPONSE IN NAÏVE CD4 T CELLS.** Zawistowska-Deniziak A.





Poster presentations

- P-1. HIGH PREVALENCE OF CARDIOPULMONARY PARASITE INFECTION IN RED FOXES (*Vulpes vulpes*) IN NW SPAIN.** [Barrera, J.P.](#)
- P-2. COMPREHENSIVE MAP OF CANINE ANGIOSTRONGYLOSIS IN DOGS IN SPAIN.** [Morchón, R.](#)
- P-3. STUDY OF ANGIOGENIC PROCESS IN AN IN-VIVO MODEL OF ENDOTHELIAL CELLS STIMULATED WITH ANTIGENS OF *DIROFILARIA REPENS* ADULTS WORMS.** [Morchón, R.](#)
- P-4. WOLBACHIA AS AN ANTIANGIOGENIC COMPONENT IN *DIROFILARIA* spp. INFECTIONS.** [Morchón, R.](#)
- P-5. MICROFILAREMIC *DIROFILARIA REPENS* INFECTION IN A SERBIAN PATIENT.** [Gabrielli, S.](#)
- P-6. COMPREHENSIVE NATIONAL SURVEY OF FELINE DIROFILARIASIS IN SPAIN.** [Carretón, E.](#)
- P-7. EXPANSION OF CANINE HEARTWORM IN SPAIN.** [Morchón, R.](#)
- P-8. *ANGIOSTRONGYLUS CHABAUDI* NATURAL INFECTION IN WILD CAUGHT GASTROPODS.** [Diakou, A.](#)
- P-9. DOES COMBINED TREATMENT FOR DIROFILARIOSIS INFLUENCE THE EXPRESSION OF GENES CODING FOR ABC TRANSPORTERS AND *WOLBACHIA* LOAD IN *DIROFILARIA IMMITIS*? RESULTS FROM AN *IN VITRO* EXPERIMENT ON ADULT WORMS.** [Vismarra, A.](#)
- P10. MAPPING THE HEARTWORM INFECTION IN THE HYPERENDEMIC ISLAND OF GRAN CANARIA (2018-2020).** [García-Rodríguez, S.N.](#)
- P-11. TRICUSPID REGURGITATION VELOCITY/PULMONARY ARTERY FLOW VELOCITY TIME INTEGRAL MEASURED BY ECHOCARDIOGRAPHY IN CANINE HEARTWORM DISEASE.** [Matos, J.I.](#)
- P-12. TOMOGRAPHIC STUDY OF PULMONARY LESIONS OBSERVED IN CATS NATURALLY INFECTED BY *DIROFILARIA IMMITIS*.** [García-Rodríguez, S.N.](#)
- P-13. IMPORTANCE OF ANAMNESIS AND PHYSICAL EXAMINATION IN CANINE HEARTWORM DISEASE.** [Matos, J.I.](#)
- P-14. TWO-DIMENSIONAL ECHOCARDIOGRAPHIC MEASUREMENTS FOR DIAGNOSIS AND STAGING OF HEARTWORM DISEASE.** [Matos, J.I.](#)
- P-15. HIGH PREVALENCE OF CARDIOPULMONARY WORMS DETECTED IN THE IBERIAN WOLF (*CANIS LUPUS*): A THREAT FOR WILD AND DOMESTIC CANIDS.** [Estévez-Sánchez, E.](#)





P-16. USEFULNESS OF THORACIC RADIOLOGICAL SIGNS FOR THE DIAGNOSIS AND STAGING OF SEVERITY IN DOGS WITH HEARTWORM. Falcón-Cordón, Y.





ABSTRACTS



Plenary presentations

I-1. HEARTWORM PANDEMIC? WHAT HAS HAPPENED TO HEARTWORM DISEASE IN EUROPE IN THE LAST 10 YEARS?

Morchón, R.¹, Rodríguez-Escolar, I.¹, Falcón-Cordón, Y.², Montoya-Alonso, J.A.², Carretón E.²

¹Zoonotic diseases and One Health group, Faculty of Pharmacy, University of Salamanca, campus Miguel Unamuno, 37007, Salamanca, Spain, rmorgar@usal.es

²Faculty of Veterinary Medicine, Research Institute of Biomedical and Health Sciences (IUIBS), University of Las Palmas de Gran Canaria, Arucas, 35413, Las Palmas, Spain.

Keywords: *Dirofilaria immitis*, Europe, heartworm, epidemiology, dog, cat, wild animals, vector

Dirofilaria immitis is the causal agent of heartworm disease in domestic and wild carnivores, mainly dogs and cats. It is a chronic disease which causes vascular damage in pulmonary arteries, and in advanced stages presence of pulmonary hypertension and right sided congestive heart failure can be evidenced. Moreover, pulmonary thromboembolism is caused by the death of the worms, which can be lethal for the infected animal. Furthermore, it is the causative agent of human pulmonary dirofilariosis, being a zoonotic disease. Its distribution is cosmopolitan, and currently *D. immitis* can be found almost anywhere in the world, from tropical to coldest climates. In Europe, the epidemiological situation in the two main hosts is markedly different. The number of studies addressing the epidemiological situation in dogs is significantly higher than in cats due to, among other factors, the difficulty in diagnosis and the number of cats compared to the number of dogs that can be accessed. From 2011, heartworm disease was considered as an endemic reality in Eastern and Centre of Europe, where it had spread from southern countries in a short period of time. Currently, the epidemiological status has continued to change, as has the number of epidemiological reports. Europe is facing new climatic conditions caused by climate change, or the presence of new competent vectors that increase the time of exposure to the parasite (daytime and crepuscular/nocturnal mosquitoes) and that widen the risk zones (mosquitoes more resistant to low temperatures, overwintering eggs, etc.). This, along with other factors, has contributed to the establishment of vectors in regions where they were not previously found. In the last 10 years, considering the epidemiological data, the possible factors influencing transmission, and forecasting studies using GIS models in different European territories, it can be stated that animal heartworm has continued to spread to Eastern and North-Eastern European countries, some of which are currently considered as new endemic countries. In other countries, isolated cases or cases imported from endemic areas have continued to appear and have even increased. Moreover, in the traditionally endemic countries of southern Europe, prevalence and seroprevalence in animals have continued to increase, except for some territories where the control measures adopted have achieved a decrease in prevalence. So, at present, most of the European continent could be considered endemic. Therefore, it is necessary to continue to conduct epidemiological and sero-epidemiological studies in animals and vectors, in order to monitor distribution trends of *D. immitis*. Specific guidelines adapted to each country would be necessary, as recommended by the European Society of Dirofilariosis and Angiostrongylosis.

References

1. European Society of Dirofilariosis and Angiostrongylosis. ESDA. Available online: <http://www.esda.vet/index.php> (accessed on 14 September 2022).
2. Fuehrer HP, Morelli S, Unterköfler MS, Bajer A, Bakran-Lebl K, et al. *Dirofilaria* spp. and *Angiostrongylus vasorum*: Current Risk of Spreading in Central and Northern Europe. *Pathogens*, 2021; 10: 1268.
3. Morchón R, Carretón E, González-Miguel J, Mellado-Hernández. I. Heartworm disease (*Dirofilaria immitis*) and their vectors in Europe – new distribution trends. *Front Physiol.* 2012; 3:196.
4. Morchón R, Montoya-Alonso JA, Rodríguez-Escolar I, Carretón E. What Has Happened to Heartworm Disease in Europe in the Last 10 Years? *Pathogens.* 2022 11:1042.





I-2. NEW DISTRIBUTION TRENDS OF VECTORS IN EUROPE

Fuehrer, H.P.^{1*}

¹Institute of Parasitology, Department of Pathobiology, University of Veterinary Medicine Vienna, Austria, hans-peter.fuehrer@vetmeduni.ac.at

Keywords: mosquito ecology, native, invasive, neo-native, tiger mosquitoes

Dirofilaria immitis and *D. repens* are mosquito-borne filarioid helminths with domestic and wild canids as main hosts and mosquitoes as vectors [1]. Both species are known to be zoonotic. *Dirofilaria repens* and *D. immitis* seem associated with climate change and a spread from historically endemic countries in Southern Europe to Central Europa was observed [2]. The vectors of *D. immitis* and *D. repens* are mosquitoes of several genera. Interestingly, competent mosquito vectors are native to European regions where these parasites were or are not present yet. With the spread of neo-native, alien, and potential invasive mosquito species additional competent vectors might establish in various regions in Europe [3]. However, most of previous studies evaluated the presence of filarioid helminths in mosquitoes using xeno-monitoring tools (e.g. pools, use of entire mosquitoes). Rarely lab-based vector competence studies or other vector competence studies have been conducted [4-5].

Therefore an overview on the current situation of mosquito vectors in Europe and their role as potential vectors for *Dirofilaria* spp. will be given.

References

1. Simón F, Siles-Lucas M, Morchón R, González-Miguel J, Mellado I, Carretón E, Montoya-Alonso JA. Human and animal dirofilariasis: the emergence of a zoonotic mosaic. Clin Microbiol Rev. 2012 Jul;25(3):507-44.
2. Fuehrer HP, Auer H, Leschnik M, Silbermayr K, Duscher G, Joachim A. *Dirofilaria* in Humans, Dogs, and Vectors in Austria (1978-2014)-From Imported Pathogens to the Endemicity of *Dirofilaria repens*. PLoS Negl Trop Dis. 2016, 10 (5): e0004547.
3. Fuehrer HP, Morelli S, Unterköfler MS, Bajer A, Bakran-Lebl K, Dwuznik-Szarek D, Farkas R, Grandi G, Heddergott M, Jokelainen P, Knific T, Leschnik M, Miterpáková M, Modrý D, Petersen HH, Skírnisson K, Vergles Rataj A, Schnyder M, Strube C. *Dirofilaria* spp. and *Angiostrongylus vasorum*: Current Risk of Spreading in Central and Northern Europe. Pathogens. 2021 Oct 1;10(10):1268. doi: 10.3390/pathogens10101268.
4. Silaghi C, Beck R, Capelli G, Montarsi F, Mathis A. Development of *Dirofilaria immitis* and *Dirofilaria repens* in *Aedes japonicus* and *Aedes geniculatus*. Parasit Vectors. 2017 10(1):94. doi: 10.1186/s13071-017-2015-x.
5. Ionică AM, Zित्रा C, Wimmer V, Leitner N, Votýpka J, Modrý D, Mihalca AD, Fuehrer HP. Mosquitoes in the Danube Delta: searching for vectors of filarioid helminths and avian malaria. Parasit Vectors. 2017 10(1):324. doi: 10.1186/s13071-017-2264-8.





I-3. MyVBDmap, THE REAL TIME WAY TO MAP CANINE VECTOR BORNE DISEASES

Varloud, M.¹, Chassain C.¹, El Ouatik Y.¹, Dupuis S.¹, Crippa A.¹

¹ Ceva Santé Animale, marie.varloud@ceva.com

Keywords: Map, Epidemiology, Distribution, Vector-borne diseases, Dog

Climate change, urbanization, invasive vector species are among the factors that favour the spread of various canine vector-borne diseases such as heartworm¹. Some of these diseases are zoonotic and the dogs can play a role of sentinel. As the changes are accelerating, the need for up to date and precise information becomes critical. Veterinarians, researchers and testing laboratories are invited to share their knowledge in real-time on a new online platform aimed at mapping clinical cases of canine vector-borne diseases: myVBDmap (<https://www.myvbdmap.com/>).

Eight canine vector-borne diseases were selected for mapping. Mosquito-borne diseases: heartworm disease (*Dirofilaria immitis*) and cutaneous dirofilariosis (*Dirofilaria repens*). Sand fly-borne disease: canine visceral leishmaniosis (*Leishmania infantum*). Tick-borne diseases: Lyme borreliosis (*Borrelia* spp.), babesiosis (*Babesia* spp.), ehrlichiosis (*Ehrlichia* spp.), anaplasmosis (*Anaplasma* spp.), tick-borne encephalitis (TBE-v).

At present, the platform is available in several languages such as French, German, Greek, Italian, Polish, Portuguese. The website may vary slightly between countries to accommodate national specificities. Only veterinary professionals and laboratory testing facilities can contribute and share new cases. The process is rapid and takes less than 2 minutes answering questions about the animal identity (to avoid double entry), the disease, the location, the endemic situation, the diagnosis method and the travel history if relevant and available. The identity information is anonymized in compliance with the RGPD rules. In case of co-infection, separated questionnaires should be filled and will be linked by the anonymized dog identity. Each case shared becomes immediately a new dot on the map for real-time implementation. The contributors can access their dashboard where the information about the cases is available and can be corrected at any time. The maps can freely be used for communication about local risk situations. If needed, a filter can be used to select one or several specific years. Most of the maps are accessible to all publics with some key information about the diseases.

MyVBDmap is the latest online tool for collaborative and real-time mapping of canine vector-borne diseases. Every shared case will contribute to a better understanding of the distribution and potential spread of these diseases. Because the more we know, the better we can fight.

References

1. Montoya-Alonso JA, Morchon R, Garcia-Rodriguez SN, Falcon-Cordon Y, Costa-Rodriguez N, Matos N, Rodriguez-Escolar I, Carreton E. Expansion of canine heartworm in Spain. *Animals*. 2022 12;1268.





I-4. THE FEMALE SIDE OF *D. REPENS*. IS IT A BREAST CANCER OR NOT?

Scoccia E.^{1*}

¹Operative Eusoma certified Unit. Maugeri Clinical-Scientific Institutes, Pavia, Italy elisabetta.scoccia@icsmaugeri.it

Keywords: Breast cancer, *D.repens*, Diagnosis, Surgery

In 2020, there were 2.3 million women diagnosed with breast cancer and 685 000 deaths globally. As of the end of 2020, there were 7.8 million women alive who were diagnosed with breast cancer in the past 5 years, making it the world's most prevalent cancer. Approximately half of breast cancers develop in women who have no identifiable breast cancer risk factor other than gender (female) and age (over 40 years)

For this reason, starting from at least 40 years of age, screening programs based on mammography and breast sonography for early diagnosis are active in many countries.

In the event of a positive result of the screening or in the presence of a suspicious clinical picture (palpable nodule), further diagnostic tests are carried out (FNAC, biopsy) to identify the neoplasm (benign or malignant) for the choice of the best surgical procedure

Unfortunately, in some cases it is not possible to determine with certainty the true nature of the neoplasm, for this reason it is necessary to resort to extemporaneous intra-operative histology on frozen specimen. However, this technique is not available on a large scale but only in hospitals where there is a Breast Unit.

The incidence of human dirofilariosis cases has increased strikingly over the last four decades in considering that humans are dead-end hosts for dirofilarial infection and most of the human cases described so far in Europe were ascribed to nodules/granuloma caused by *D. repens*. quite frequently in breast subcutaneous tissues in middle age woman (> 40 year old).

In our Hospital experience mammography, breast sonography, cytology result were not able to rule out a malignant neoplasia in the face of *D.repens* nodule and only intra-operative histology correctly identified the problem allowing a scarcely invasive surgical procedure (nodulectomy) instead of a more demolitive intervention (quadrantectomy) with the need for reconstructive surgery to avoid aesthetic damage which happens or could happen in hospitals that do not have a Breast Unit.

Nonetheless, despite Italy being the country with the highest number of human clinical cases a general lack of awareness of this zoonotic parasitic disease persists and many surgeons do not even know the problem.

For this reason, a reduction in the spread of the parasite, a greater integration between surgeons and veterinarians in the One Health concept, and specific diagnostic investigations for the diagnosis of *D. repens* in humans are highly desirable and a goal to pursue.

References

1. Coughlin SS. Epidemiology of Breast Cancer in Women. *Adv Exp Med Biol.* 2019;1152:9-29.
2. Gabrielli S, Mangano V, Furzi F, Oliva A, Vita S, Poscia R, Fazii P, Di Paolo J, Marocco R, Mastroianni CM, Bruschi F, Mattiucci S. Molecular Identification of New Cases of Human Dirofilariosis (*Dirofilaria repens*) in Italy. *Pathogens.* 2021 Feb 23;10(2):251.





I-5. HUMAN ANGIOSTRONGYLIASIS IN EUROPE

Paredes-Esquivel, C.¹

¹Department of Biology. Universitat de les Illes Balears. Palma, Spain, claudia.paredes@uib.es

Keywords: angiostrongyliasis, angiostrongylus, cantonensis, rat lungworm, Europe

Neuroangiostrongyliasis is an emerging zoonosis caused by the rat lungworm, *Angiostrongylus cantonensis*. In humans, the infection can cause a painful and complicated eosinophilic meningitis and it often occurs after the inadvertent ingestion of uncooked gastropods. Prevalence rates of neuroangiostrongyliasis have increased dramatically in recent years across the world. Europe was considered a non-endemic area, until 2019, when we reported the presence of the rat lungworm in Mallorca (Spain) in wild, neurologically distressed hedgehogs that were rescued by concerned citizens. Of relevance to the transmission cycle, we have also recently detected *A. cantonensis* in island rats, the classic definitive host. Given the heavy influx of ships between Mallorca and continental Europe, *A. cantonensis* is likely to be distributed in other regions of the continent. Then, active surveillance should be conducted in all areas where the parasite may become established since early diagnosis is essential for a better prognosis of affected patients. Adopting a One Health approach is a cost-effective strategy for the early detection of the rat lungworm in other regions of Europe.





I-6. DIROFILARIASIS (HEARTWORM DISEASE) IN FERRETS

Montesinos, A.^{1,2}

¹Director of Exotic Animals Hospital Los Sauces, Madrid, Spain

²Associate Professor of Exotic Animals Medicine and Surgery in the School of Veterinary Medicine of Universidad Complutense, Madrid, Spain.

Keywords: Heartworm, ferrets, ultrasound, treatment, diagnostic.

Dirofilariasis is an uncommon disease in domestic ferrets, caused by an infection with *Dirofilaria immitis*.¹ The susceptibility and life cycle of *D. immitis* have been studied extensively in ferrets and were found to be similar to those in dogs.² However because the ferret's small size, the clinical presentation more closely resembles that of infected cats. Worms may reside in the right ventricle, cranial vena cava, or main pulmonary artery and cause villous endarteritis.³ Although natural infections with worm burdens of up to 21 worms have been reported, ferrets may already develop severe heart disease by the presence of a single worm, due the small size of the ferret's heart. As few as two adult heartworms may result fatal right-sided heart failure, especially if the worm's presence causes a mechanical obstruction of the blood flow.^{3,4} Ferrets that live in or originated from heartworm-endemic areas, especially those kept outdoors, are considered most at risk to develop disease.^{5,6} Clinical signs of heartworm disease in ferrets are similar to those observed in dogs, and may range from asymptomatic individuals to sudden death. Other clinical signs that have been reported include anorexia, lethargy, weakness, depression, dyspnea, tachypnea, cyanosis, coughing, pale mucous membranes and abdominal distension.^{1,5,7} Caval syndrome and aberrant larval migration, with associated CNS signs, have also been documented in ferrets with a *D. immitis* infection.⁸ As in dogs, the diagnosis of heartworm disease in ferrets is usually based on clinical signs, combined with radiographic and ecocardiographic findings, and testing for circulating microfilariae and heartworm antigen.^{3,7,9} Heartworm-infected ferrets have low, transient concentrations of microfilaria, making microfilaria detecting tests unreliable. ELISA-based antigen tests (IDEXX Snap heartworm antigen test) have been shown to be effective 5 to 6 months after infection but may produce false-negative results because of low worm burdens. Adult worms may be detected by ultrasound as early as 5 months after infection in the cranial vena cava and right side of the heart. The small numbers of heartworms in these animals also necessitates the use of occult heartworm tests because of absent or low numbers of circulating microfilaria. DNA-based polymerase chain reaction assays are capable of sensitive and specific identification of the *D. immitis* genetic material in blood specimens. Polymerase chain reaction assay is so sensitive that even a single heartworm cell can be detected, and it can be used for early detection of heartworm infection.¹ This diagnostic approach to heartworm detection in ferrets needs to be further developed and validated.

Treatment options for ferrets with heartworm disease include adulticide therapy combined with symptomatic treatment to alleviate the clinical signs that result from the right-sided heart failure. The currently recommended treatment protocol for ferrets with heartworm disease includes ivermectin, which needs to be administered until clinical signs resolve and microfilaremia is no longer present.^{1,4,10} Adulticide treatments are similar to those used in dogs. Transvenous heartworm extraction is nowadays also considered a viable option.⁸ To avoid the risk of complication from worm emboli, treatment with prednisone is often initiated concurrently with the adulticide treatment and continued for at least 4 weeks. Whether pre-treatment with doxycycline for *Wolbachia* will enhance the efficacy of heartworm therapy in ferrets, similar to dogs, is currently not known.¹

Control is best achieved through monthly administration of a heartworm preventive to ferrets in endemic area. Prognosis is considered fair to guarded for ferret with asymptomatic infection and it's serious in animals with moderate to severe infections.^{3,11}

References

1. McCall JW. Dirofilariasis in the domestic ferret. Clin Tech Small Anim Pract. 1998;13(2):109-112. doi:10.1016/S1096-2867(98)80015-7
2. Campbell WC, Blair LS. Dirofilaria immitis: experimental infections in the ferret (Mustela putorius furo). J Parasitol. 1978;64(1):119-122. doi:10.2307/3279620
3. Parrott TY, Greiner EC, Parrott JD. Dirofilaria immitis infection in three ferrets. J Am Vet Med Assoc. 1984;184(5):582-583.
4. Supakorndej P, McCall JW, Jun JJ. Early migration and development of Dirofilaria immitis in the ferret, Mustela putorius furo. J Parasitol. 1994;80(2):237-244.





5. Mulreany LM, Niedringhaus KD, Fenton HMA, et al. Filarial dermatitis caused by *Filaria taxideae* in domestic ferrets (*Mustela putorius furo*) from the western United States. *Vet Parasitol Reg Stud reports*. 2018;14:155-160. doi:10.1016/J.VPRSR.2018.10.011
6. Molnár V, Pazár P, Rigó D, et al. Autochthonous *Dirofilaria immitis* infection in a ferret with aberrant larval migration in Europe. *J Small Anim Pract*. 2010;51(7):393-396. doi:10.1111/J.1748-5827.2010.00950.X
7. Campbell WC, Blair LS. *Dirofilaria immitis*: experimental infections in the ferret (*Mustela putorius furo*) part 2. *J Parasitol*. 1978;64(2):145-162.
8. Bradbury C, Saunders AB, Heatley JJ, Gregory CR, Wilcox AL, Russell KE. Transvenous heartworm extraction in a ferret with caval syndrome. *J Am Anim Hosp Assoc*. 2010;46(1):31-35. doi:10.5326/0460031
9. Sasai H, Kato K, Sasaki T, Koyama S, Kotani T, Fukata T. Echocardiographic diagnosis of dirofilariasis in a ferret. *J Small Anim Pract*. 2000;41(4):172-174. doi:10.1111/j.1748-5827.2000.tb03189.x
10. Blair LS, Campbell WC. Suppression of maturation of *Dirofilaria immitis* in *Mustela putorius furo* by single dose of ivermectin. *J Parasitol*. 1980;66(4):691-692. doi:10.2307/3280538
11. Ionică AM, Matei IA, D'Amico G, et al. Filarioid infections in wild carnivores: A multispecies survey in Romania. *Parasites and Vectors*. 2017;10(1). doi:10.1186/s13071-017-2269-3



I-7. THE ROLE OF ULTRASOUNDS FOR THE DIAGNOSIS OF *D. IMMITIS* AND *D. REPENS* INFECTION IN DOGS

Venco, L.¹

¹ Ospedale veterinario Città di Pavia, Pavia Italy, luigivenco@libero.it

Keywords: *D. immitis*, *D. repens*, US, Dogs

Ultrasound is a pivotal tool in the field of internal medicine and the technological evolutions that have led to the possibility of using small, high-tech and low-cost US machines continuously multiply its applications. In the field of clinical parasitology, in particular, it is very useful for proper diagnostic purposes (visualization of the parasites) but also in the staging of the patient and in his follow-up to evaluate the damage induced by the parasites themselves. Regarding Heartworm Disease, the same kind of investigation has 2 different clinical applications. In dogs, it is possible and sometimes easy visualize the parasites into the pulmonary arteries and into the right heart chambers in case of Caval Syndrome confirming or denying the result of antigen tests on blood sample. However, it is essential that the echocardiographic examination is not a standard investigation but is focused on the pulmonary arteries, in particular the right up to its bifurcation. With such a focused echocardiographic investigation, in a set of 38 dogs in which the sure diagnosis of natural infection was made with the simultaneous positivity of the Antigen and the Knott test it was possible to directly visualize adult *D. immitis* into the pulmonary arteries in 33 cases, regardless of size and presence of pulmonary hypertension with a sensitivity of 87%.

The second point the investigation is mainly aimed at staging the patient helping in the estimate of the worm burden, fundamental for the choice of the therapy, but also through some parameters (dilation of the pulmonary arteries, velocity of tricuspid and pulmonary regurgitation, RPAD Index) in detecting and quantifying the states of pulmonary hypertension which are the main noxa induced by *D. immitis* in this species.

About *D. repens* in dogs with skin nodular manifestations only, US allows the direct visualization of the adult worms. leading directly to the diagnosis and allowing immediately to rule out the neoplastic pathology (mast cell tumor) versus which for the clinical aspects (Darrier's sign) differential diagnostics is imposed. US may furthermore guide the minimally invasive removal of the parasites.

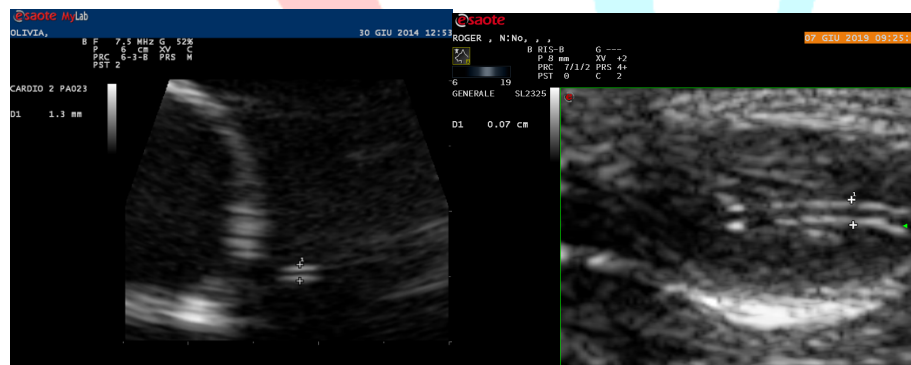


Figure 1. US visualization of adult *D. immitis* into the main pulmonary artery (left) and adult *D. repens* into a skin granuloma (right).

References

1. McCall JW, Genchi C, Kramer LH, Guerrero J, Venco L. Heartworm disease in animals and humans Adv Parasitol. 2008;66:193-285.
2. Albanese F, Abramo F, Braglia C, Caporali C, Venco L, Vercelli A, Ghibauda G, Leone F, Carrani F, Giannelli A, Otranto D. Nodular lesions due to infestation by *Dirofilaria repens* in dogs from Italy Vet. Dermatol., 24 (2013), pp. 255-256



I-8. NEW BIOMARKERS IN HEARTWORM DISEASE

Carretón, E.¹, Costa-Rodríguez, N.¹, Falcón-Cordón, Y.¹, Morchón, R.^{1,2}, Montoya-Alonso, J.A.¹

¹Faculty of Veterinary Medicine, Research Institute of Biomedical and Health Sciences (IUIBS), University of Las Palmas de Gran Canaria, Arucas, 35413, Las Palmas, Spain, elena.carreton@ulpgc.es

²Zoonotic diseases and One Health group, Faculty of Pharmacy, University of Salamanca, campus Miguel Unamuno, 37007, Salamanca, Spain.

Keywords: biomarkers, heartworm, troponin I, N-terminal pro-B-type natriuretic peptide, dogs.

Cardiorespiratory function in dogs infected with *Dirofilaria immitis* is routinely evaluated through tests such as radiography, echocardiography, and electrocardiography. However, serological biomarkers show that they can be a very useful tool in most cases, providing additional information to the clinical veterinarian. The most widely used biomarkers in small animals' cardiology are cardiac Troponin I (cTnI) and the N-terminal pro-B-type natriuretic peptide (NT-proBNP), which have also shown a great utility in the evaluation of heartworm disease. Numerous studies indicate that troponin I is significantly elevated in chronic infections when compared to dogs with recent infections, so its use has proven to be useful when evaluating chronicity, response to treatment, and myocardial damage caused by this infection. Similarly, it has been seen that NT-proBNP values increase in the most severe stages, and a relationship has been observed between the presence of pulmonary hypertension and pathological increases in NT-proBNP, so this biomarker could be useful to evaluate this condition, which is so frequent in canine heartworm. Similarly, it has been observed that endothelin-1 (ET-1) acts as a good marker to assess the presence and severity of pulmonary hypertension in dogs with *Dirofilaria immitis*. Moreover, in a recent study, it has been observed that this biomarker remains increased in dogs in which pulmonary hypertension persists several months after completion of adulticide treatment. Undoubtedly, D-dimer is another very useful biomarker in canine heartworm, since it helps in the detection of pulmonary thromboembolism, a very frequent phenomenon in this pathology. Several studies support its use, especially during adulticide treatment, when adult parasites are dying and the risk of severe thromboembolism is greater. Given the important inflammatory component of this disease, it is not surprising that acute phase proteins (APP) have also shown utility in diagnosing and establishing severity. Among the different APP available, the study of C-reactive protein stands out, which has been shown to be useful in the diagnosis of pulmonary hypertension in various studies. Furthermore, studies in this field continue, with the evaluation of biomarkers such as cortisol, oxidative stress markers or interleukins, to give a few examples. All biomarkers have limited utility and should not be used as a sole diagnostic method, but rather in combination with other diagnostic techniques. However, their simplicity when it comes to obtaining and interpreting make them great allies in the veterinary clinic. To consolidate their use, it is necessary to establish standardized reference values as well as the creation of protocols for use based on the different stages of the disease.

References

1. Carretón E, Cerón JJ, Martínez-Subiela S, Tvarijonaviciute A, Caro-Vadillo A, Montoya-Alonso JA. Acute phase proteins and markers of oxidative stress to assess the severity of the pulmonary hypertension in heartworm-infected dogs. *Parasit Vectors*. 2017;10(Suppl 2):477.
2. Carretón E, Corbera JA, Juste MC, Morchón R, Simón F, Montoya-Alonso JA. *Dirofilaria immitis* infection in dogs: cardiopulmonary biomarker levels. *Vet Parasitol*. 2011;176(4):313–6.
3. Carretón E, Morchón R, González-Miguel J, Juste MC, Simón F, Montoya-Alonso JA. Utility of cardiac biomarkers during adulticide treatment of heartworm disease (*Dirofilaria immitis*) in dogs. *Vet Parasitol*. 2013;197(1–2):244–50.
4. Carretón E, Morchón R, Montoya-Alonso JA. Cardiopulmonary and inflammatory biomarkers in heartworm disease. *Parasit Vectors*. 2017; 10(Suppl 2):534
5. Falcón-Cordón Y, Tvarijonaviciute A, Montoya-Alonso JA, et al. Evaluation of acute phase proteins, adiponectin and endothelin-1 to determine vascular damage in dogs with heartworm disease (*Dirofilaria immitis*), before and after adulticide treatment. *Vet Parasitol*. 2022; 309:109759
6. Méndez JC, Carretón E, Martínez S, Tvarijonaviciute A, Cerón JJ, Montoya-Alonso JA. Acute phase response in dogs with *Dirofilaria immitis*. *Vet Parasitol*. 2014; 204(3–4):420–5.
7. Yoon WK, Kim YW, Suh SL, Choi R, Lee SG, Hyun C. Evaluation of cardiopulmonary and inflammatory markers in dogs with heartworm infection during treatment with the 2014 American Heartworm Society recommended treatment protocol. *Parasit Vectors*. 2017; 10(Suppl 2):535.





I-9. CAN WE DIAGNOSE *DIROFILARIA REPENS*?

Genchi, M.¹

¹ Department of Veterinary Science, University of Parma, Parma, Italy, marco.genchi@unipr.it

Keywords: *Dirofilaria repens*, Diagnosis, Knott's test, PCR

Dirofilaria repens (subcutaneous dirofilariosis) is a vector-borne parasitic zoonotic infection that can infect numerous mammalian species (McCall et al., 2008). Subcutaneous dirofilariosis is considered an emerging problem in veterinary and human medicine. *D. repens* is present in Europe, Africa and Asia, and its distribution range is constantly increasing. In dogs and cats, this disease is often considered asymptomatic. In view of the fact that *D. repens* is probably the most common cause of zoonotic dirofilariosis in Europe, a correct diagnosis is fundamental.

Currently, in the absence of an antigen test, visualization and morphological identification of the blood-circulating microfilariae, modified Knott's test, is the best and most sensitive and specific option for diagnosis of *D. repens* infection, even when compared to molecular methods such as PCR (Ciuca et al., 2020). However, the toxicity, special precautions in handling and disposal of formalin, are some of the problems that limit the use of this tool by practitioners. Recently it has been demonstrated how formalin can be replaced by distilled water in Knott's test, keeping the morphology of the microfilariae unchanged (Genchi et al., 2021). During the identification of circulating microfilariae, it is essential to consider, in addition to the characteristic shape of the umbrella-shaped tail, also other parameters such as: length, width and shape of the head.

In cases where one or more nodules are present, diagnosis can also be aided by fine needle sampling and subsequent cytological examination (identification of microfilariae) or by ultrasound (presence of adult worm). On macroscopic examination, the cuticle of *D. repens* adult worms is whitish, with distinct longitudinal ridges on the surface. These crests allow the species identification also on histological examination.

References

1. McCall JW, Genchi C, Kramer LH, Guerrero J, Venco L. Heartworm disease in animals and humans. *Adv Parasitol.* 2008;66:193-285.
2. Ciuca L, Vismarra A, Lebon W, Beugnet F, Morchon R, Rinaldi L, Cringoli G, Kramer L, Genchi M. New insights into the biology, diagnosis and immune response to *Dirofilaria repens* in the canine host. *Vet Parasitol.* 2020;277S:100029.
3. Genchi M, Ciuca L, Vismarra A, Ciccone E, Cringoli G, Kramer L, Rinaldi L. Evaluation of alternative reagents on the performance of the modified Knott's test. *Vet Parasitol.* 2021 Oct;298:109555.





I-10. IS IT HARD? DIAGNOSIS AND MANAGEMENT OF FELINE HARD

García-Guasch, L.^{1,2,3}; Montoya-Alonso, J.A.³; Carretón, E.³

¹ Cardiology & Respiratory Medicine, IVC Evidencia - Hospital Veterinari Molins, Barcelona, Spain. laingarcia@gmail.com

² Cardiology, IVC Evidencia - Hospital Veterinaria del Mar, Barcelona, Spain.

³ Internal Medicine, Faculty of Veterinary Medicine, Research Institute of Biomedical and Health Sciences, University of Las Palmas de Gran Canaria, Las Palmas de Gran Canaria, Spain.

Keywords: HARD, Feline Heartworm, *Dirofilaria immitis*

For feline practitioners, the cat with a cough or respiratory distress and thoracic radiographs with a bronchial or bronchointerstitial pattern suggests lower airway disease. Allergic asthma and feline heartworm disease (FeHW) are two important differentials as both diseases overlap clinicopathologic features. Discriminating between both diseases can be challenging. To achieve it, it is necessary to incorporate a signalment, a complete history and carefully analyze the clinical signs, diagnostic imaging, blood tests for heartworm infection and other ancillary tests.

In FeHW patients, death of immature worms incites an intense inflammatory response leading to airway, interstitial and vascular changes in the pulmonary parenchyma defined as Heartworm Associated Respiratory Disease (HARD). Nevertheless, adult heartworms suppress the feline immune system, leading to a relative anti-inflammatory state that minimizes the development of clinical signs. When they die, intense inflammation and thromboembolism can occur triggering a high mortality probability and a guarded prognosis.

Feline asthma is a chronic respiratory disorder characterized by eosinophilic airway inflammation, airway hyperresponsiveness, airflow limitation and airway remodeling. In stable asthmatic cats, the classic history is chronic and/or episodic with complaints of cough, wheeze and increased respiratory rate or effort. Asthmatic cats with an unstable presentation present in crisis with open-mouth breathing, tachypnea and/or increased expiratory effort with an abdominal 'push'. In asthma morbidity is relatively high but mortality is low with an overall good to excellent prognosis.

Clinical signs of FeHW depend on the stage of infection and response of the host. Heartworm infection in cats is basically pulmonary in nature and clinical signs vary in severity and type, ranging from asymptomatic to signs of lethargy, coughing, tachypnea and respiratory distress. Respiratory distress is generally mixed, with increased effort both on inspiratory and expiratory phases, and not predominantly expiratory distress as in feline asthma.

As with asthma, thoracic radiographs in cats with HARD can be non-specific and may not show any overt abnormalities. Echocardiography is useful to help clarify if cardiovascular changes are due to the presence of adult heartworms or another primary cardiovascular disorder. Bronchoalveolar lavage is useful to rule out disease mimics (eg, presence of *Aelurostrongylus* larvae, or non-septic suppurative inflammation in chronic bronchitis) and secondary bacterial infection. Both asthma and heartworm disease are associated with a nonspecific increase in eosinophil percentages. The bronchial reaction associated with FeHW can be functionally assess by barometric whole-body plethysmography, a non-invasive pulmonary function test, that confirms the diagnosis of pathological states of bronchoconstriction in both HARD and asthmatic cats.

However, in terms of cause, disease progression, treatment and prognosis, it is important to confirm the diagnosis since asthma is treatable while FeHW is preventable.

References:

1. Dillon AR, Tillson DM, Wooldridge A, et al. Effect of pre-cardiac and adult stages of *Dirofilaria immitis* in pulmonary disease of cats: CBC, bronchial lavage cytology, serology, radiographs, CT images, bronchial reactivity, and histopathology. *Vet Parasitol* 2014; 206: 24–37.
2. Garcia-Guasch L, Caro-Vadillo A, ManubensGrau J, et al. Is *Wolbachia* participating in the bronchial reactivity of cats with heartworm associated respiratory disease? *Vet Parasitol* 2013; 196: 130–135.





I-11. UPDATE AND TRENDS IN FELINE EPIDEMIOLOGY

Carretón, E.¹, Montoya-Alonso, J.A.¹, Rodríguez-Escolar, I.², Matos, J.I.¹, García-Rodríguez, S.N.¹, Morchón, R.^{1,2}

¹Faculty of Veterinary Medicine, Research Institute of Biomedical and Health Sciences (IUIBS), University of Las Palmas de Gran Canaria, Arucas, 35413, Las Palmas, Spain, elena.carreton@ulpgc.es

²Zoonotic diseases and One Health group, Faculty of Pharmacy, University of Salamanca, campus Miguel Unamuno, 37007, Salamanca, Spain.

Keywords: cats, dirofilariasis, epidemiology, Europe

The epidemiology of canine heartworm disease is well known in Europe. It is known that it is an emerging disease, expanding for at least 15 years. However, the number of publications on the epidemiology of feline heartworm is still scarce. Even in those countries considered endemic, studies on the feline species are very few and not widespread, often limited to the study of clinical cases. Among the reasons, there is the difficulty in diagnosing this pathology in the feline species. Also, that the symptoms are often confused with other more frequent respiratory diseases. Furthermore, many cats tolerate the infection without any noticeable clinical signs or with signs manifested only transiently; sometimes, sudden death may arise without warning. Although timidly, the number of studies has been increasing, thanks to a greater awareness of the disease in this species, outlining an epidemiological picture of feline heartworm similar to that of canines, demonstrating the spread of this parasitic disease among cats as well. Its presence is consolidated in endemic countries such as Spain, Portugal, Italy and Greece, where published studies are increasing. In Spain, a recent study has reported a seroprevalence of 9.4%, with a similar distribution to canines: the highest seroprevalences were reported in the Canary Islands (19.2%), Balearic Islands (16%) and Mediterranean coast (9.2–11.2%). The case of the Canary Islands is especially noteworthy, where an increase in seroprevalence in cats has been observed over the years, contrary to what happens in dogs. On the other hand, cases have also been described in the north of the country, until recently considered free of the disease. In Portugal, feline prevalence studies are relatively recent, but demonstrate the important presence of this parasite in the cats living in the country. The different seroprevalences reported varied from 15% in the center of Portugal, 17.5% in the north-center, 5% in southern Portugal, or recently a prevalence of 3.5% in Madeira, an island of which a high prevalence in dogs was already known. In Italy, *D. immitis* is endemic in northern Italy and has now spread all over the country, which shows a current change of distribution of this parasite throughout the Italian territory while canine and feline heartworm infection is more frequently diagnosed in southern regions. Feline heartworm showed varied prevalences in northern Italy, between 7 and 27%. In regions of central Italy heterogeneous prevalences were reported as well (from 0.3% to 23.5%). Furthermore, new infections have been reported in southern Italy. In Greece, the first feline study was carried out in the north of the country, reporting a prevalence of 3%. The first descriptions are also beginning to appear in new endemic countries: interestingly, microfilariae of *D. immitis* were detected in the urine, but not in the blood, of a cat in southern France. In Germany, a retrospective study from 2012 to 2020 identified heartworm in three cats in 2012, while in Austria, the first case of autochthonous feline heartworm is published in 2012. In Bulgaria and Romania, the first reports on feline *D. immitis* infection also have been documented.

References

1. Morchón R, Carretón E, González-Miguel J, Mellado-Hernández I. Heartworm Disease (*Dirofilaria immitis*) and Their Vectors in Europe - New Distribution Trends. *Front Physiol.* 2012 Jun 12;3:196.
2. Morchón R, Montoya-Alonso JA, Rodríguez-Escolar I, Carretón E. What Has Happened to Heartworm Disease in Europe in the Last 10 Years? *Pathogens.* 2022 11:1042.





I-12. COMBINATION OF FLURALANER AND MOXIDECTIN TO PROTECT CATS FROM HEARTWORM INFECTIONS FOR 12 WEEKS.

Drake, J.¹

¹Merck Animal Health, Madison, NJ, USA, jason.drake@merck.com

Feline heartworm disease prevention is made even more important due to the lack of approved heartworm treatments for cats because infection can result in severe respiratory disease and even sudden death. Veterinary teams do not always place the same emphasis on prevention in cats when compared to dogs, and prevalence of infection in cats has been reported to be 5-20% the local prevalence in dogs.

Traditionally, monthly heartworm preventive efficacy was demonstrated by administering preventive products 30 days following infection with L3 larvae of *Dirofilaria immitis*. The advent of formulations which provide persistent levels of active ingredients over several weeks instead of only a few hours or days has resulted in the ability to demonstrate efficacy at various time points after administration of the product. Results of efficacy against *D. immitis* L3 infections 60- and 90-days following administration will be reviewed.





I-13. DIAGNOSIS AND TREATMENT OF FELINE HEARTWORM DISEASE. WHAT IS NEW?

Venco, L.¹

¹ Ospedale veterinario Città di Pavia, Pavia Italy, luigivenco@libero.it

Keywords: *D. immitis*, Cats, Diagnosis, Treatment

Feline heartworm disease is a very different clinical entity from canine heartworm disease. In cats, the arrival and death of immature heartworms in the pulmonary arteries can cause coughing and dyspnea as early as 3 months postinfection such as the death of adult worms after 2-3 years post infection. Adult heartworms suppress the function of pulmonary intravascular macrophages and thus reduce clinical disease in chronic feline heartworm infection. Approximately 80% of asymptomatic cats self-cure. Median survival time for symptomatic cats is 1.5 years, or 4 years if only cats living beyond the day of presentation are considered. Severe respiratory distress and sudden death can occur with no prior clinical signs. The prevalence of feline heartworm infection, less well defined because definitive antemortem diagnosis is difficult to achieve, is generally estimated to be 10% that of the canine population in the same area

Unfortunately, the diagnosis, treatment, and management of feline heartworm disease are far from simple. Antemortem diagnosis is hampered by low worm burdens, the frequency of all-male infections, and nonspecific radiographic lesions. In contrast to dogs, both microscopical detection of microfilariae and ELISA or immunochromatographic (IC)-based tests that detect circulating antigens of adult *D. immitis* females have low sensitivity in cats. Anti-*D. immitis* antibodies are found about 2 months post infection and they confirm exposure to *D. immitis*. However, a risk of false positive results exists because of antibody persistence even in cats that have cleared the parasites. False negative results are also possible (particularly in asymptomatic cats), and a wide range of sensitivities exist among the different tests. The combined use of antigen and antibody testing increases diagnostic accuracy of testing for feline HWD but negative results on both tests still cannot rule out a diagnosis in suspected HARD cases. Heat treatment of serum (103 °C for 10 min) prior to antigen testing has been shown to result in an increase in positive antigen test results, presumably due to disruption of natural antigen-antibody complexes and in cats could be a useful diagnostic tool in case of suspicion. Echocardiography is anyway the diagnostic tool of choice combining high sensitivity and specificity. Due to the length of the parasite and the shortened length of the pulmonary arteries which can be largely visualized a carefully diagnostic echocardiographic examination may virtually visualize even a single adult worm

Treatment is symptomatic and mainly based on the administration of corticosteroids because adulticide and surgical therapy are risky and does not increase survival time. Despite the dangers of feline heartworm disease with unpredictable and potentially fatal course and the lack of safe and effective treatments, few cats are on chemoprophylaxis. It is important for veterinarians to take a proactive preventive stance suggesting chemoprophylaxis in endemic areas, for all cats – irrespective of their access to outdoors.

References

1. Venco L, Marchesotti F, Manzocchi S. Feline heartworm disease: A 'Rubik's-cube-like' diagnostic and therapeutic challenge. *J Vet Cardiol.* 2015 Dec;17 Suppl 1:S190-201.
2. Gruntmeir JM, Adolph CB, Thomas JE, Reichard MV, Blagburn BL, Little SE. Increased detection of *Dirofilaria immitis* antigen in cats after heat pretreatment of samples. *J Feline Med Surg.* 2017 Oct;19(10):1013-1016.





I-14. HEARTWORM MANAGMENT IN NON ENDEMIC AND NEW ENDEMIC AREAS

Curcin, Lj.¹

¹Veterinary Clinic Intervet, Belgrade, Serbia, vetintervet@yahoo.com

Keywords: heartworm, non endemic, new endemic

Endemic (of a disease or condition) regularly found among particular people or in a certain area – area where heartworm disease is endemic.

For the spread Htw it is necessary to met more conditions:

- Reservoir – wild animals, infected dogs.
- Infected mosquitoes.
- Access – exposed animals.
- Protection – inadequate protection for *Dirofilaria*.

In non endemic areas thinking of veterinarian and the owner about the presence of Htw is occasional, only veterinarians suspect of the Htw at DCM. Increased number of infected dogs is connected to slow clinical image of disease.

The simplest ways of infection of dogs in non endemic areas are:

- Traveling of non infected dogs to endemic areas without adequate protection against *Dirofilaria*.
- Traveling of infected dogs to non endemic areas.

Such dogs became source for spreading parasites in non endemic areas.

On the European continent climate changes led to higher spread of Htw disease because the climate becomes more suitable for mosquitoes and their activity.

Recommendation for non endemic and new endemic areas is an annual testing , giving preventives in the season of the mosquitoes activity, suppression of vector and education of the veterinarians and population.





I-15. HEARTWORM MANAGEMENT AND PREVENTION. A REVIEW: ASSESSMENT OF RAPID IMMUNOCHROMATOGRAPHIC TESTS AND SELAMECTIN TOPICAL ROUTE.

Addali Alvarez, A¹.

¹Global Marketing & Medical Manager Parasitocides. Companion Animals Virbac, ahmed.addalialvarez@virbac.com

Keywords: diagnostics, prevention, heartworm, Speed Diro™, Selamectin.

The aim of this presentation is to emphasize the importance of systematic Dirofilariasis screening with proper diagnostic tools, as well as the need to prevent it in dogs and cats with effective and safe products.

DIAGNOSTICS: According to (1): the performance of a rapid immunochromatographic test for the detection of *Dirofilaria immitis* antigens (Speed Diro™; BVTVirbac, France) was assessed in 49 experimentally infected dogs and in 244 naturally infected animals; 142 dogs and 102 cats. In experimentally infected dogs, Speed Diro™ showed a sensitivity of 90.9% in dogs infected with one adult female worm and 100% in dogs infected with more than one female worm. Specificity was 100%. For naturally infected dogs, the Knott test and PetChek® HTWMPF served as reference methods for microfilaremia and antigenemia, respectively. All microfilaemic dogs (55/142) were positive with Speed Diro™. Importantly, none of the 21 dogs infected with *D. repens* were positive. The results of SpeedDiro™ for the detection of antigenemia were compared with two in-house tests, SNAP® HTW and Witness® Dirofilaria, and all three tests were 100% specific and sensitive in comparison to PetChek® HTWMPF. For the evaluation of feline samples, 102 cats were examined by echocardiography. Sera from 87 heartworm-infected cats were tested by Speed Diro™ and SNAP® HTW. The results of Speed Diro™ were equivalent to SNAP® HTW, with a sensitivity of 98.9% and a specificity of 100%.

PREVENTION: Canine and Feline heartworm infection is preventable and therefore, chemoprophylaxis is a priority in heartworm endemic areas. Reducing the reservoir population is one of the goals of prevention and also, decreasing the prevalence of infection among unprotected dogs and cats. For that purpose, macrocyclic lactones (like selamectin) are the most commonly used because they are safe and effective.

- According to (2): this study was conducted to confirm the efficacy of 6% Selamectin Spot Product (Evicto®, Virbac) by comparing the efficacy in preventing infection with heartworm (*Dirofilaria immitis*) in cats with the approved drugs (6% Stronghold®/Revolution®). 18 cats, each infected with approximately 100 heartworm 3-stage larvae (L3) on Day -30, were induced by subcutaneous injection, and a test drug was administered on Day 0. Necropsy was performed on Day 152 to count the number of heartworms. Following regulatory Guidelines VICH GL20.

The animals were tested for heartworm antigen on Day 89, and clinical signs were observed daily from the start of acclimatization to the day of necropsy. The establishment of the study was considered to be the presence of at least 1 adult worm infection in each of the 6 cats in the NEGATIVE CONTROL group. The counting of heartworms on Day 152 confirmed that all 6 cats in the NEGATIVE CONTROL group were infected with at least 1 adult worm. Therefore, it was judged that the criteria of study conditions were met. The results showed that the percentage reduction of the number of worms in the IVP group and the POSITIVE CONTROL group to the NEGATIVE CONTROL group were both 100%. Statistically, the infection counts in the IVP group and the POSITIVE CONTROL group were significantly lower than those in the NEGATIVE CONTROL group ($P < 0.05$). There were no significant differences between the IVP group and the POSITIVE CONTROL group ($P \geq 0.05$). Mild respiratory distress was observed in the animal number T10SMC (NEGATIVE CONTROL group) on Day 145, but recoveries were confirmed on Day 146 without any treatment. The cat has the highest number of worms confirmed at necropsy. No other abnormal clinical signs observed in any other animals throughout the study period. Based on the results, the single dermal administration of the test drugs Evicto® showed 100% preventive efficacy against heartworm infection in cats, equivalent/ non-inferiority to that of the approved drugs Revolution®/Stronghold® 6%.

According to (3): this study was conducted to determine the efficacy of investigational veterinary products which contains Selamectin as an active ingredient (Evicto®, 6% and 12% solutions) against heartworm (*Dirofilaria immitis*) in dogs by comparing with the existing approved drugs (Revolution®/Stronghold® 6% and 12% solutions). Following all Regulatory requirements of Guidelines VICH GL19. On Day -30 (± 1), each of twenty-four dogs was infected subcutaneously with approximately 100 heartworm 3-stage larvae (L3) (Parasite Inoculation Form). Animals were administered the test drugs on Day 0, and necropsy was performed on Day 121 to count the number of heartworms. The animals were tested for heartworm antigen (Blood Sampling Form and Heartworm Antigen Test Form) on Day 90. Clinical signs were observed daily from the start of acclimatization to the day of necropsy.

The establishment of the model was considered with the presence of at least 1 adult worm in at least 6 dogs in the NEGATIVE CONTROL group. The counting of heartworms on Day 121 confirmed that all eight dogs in the NEGATIVE CONTROL group were infected with at least one adult worm. Therefore, it was judged that the criteria of study conditions were met. The results expressed the percentage reduction of the number of worms in the IVP groups and POSITIVE CONTROL groups





compared to the NEGATIVE Control Group All the IVP and the POSITIVE CONTROL groups were 100% effective. Statistically, the infection counts in the IVP groups and POSITIVE CONTROL groups were significantly lower than those in the NEGATIVE CONTROL group ($P < 0.05$). There were no significant differences between the IVP groups and the POSITIVE CONTROL groups ($P \geq 0.05$). No abnormal clinical signs were observed in all dogs. Based on the results, the single dermal administration of the IVP drugs Evicto® (6% and 12% solutions) showed 100% preventive efficacy against heartworm infection in dogs, equivalent/non-inferiority to that of the approved drugs Revolution®/Stronghold® (6% and 12% solutions)

References

1. Genchi, M., Mangia, C., Ferrari, N., Loukeri, S. Evaluation of a rapid immunochromatographic test for the detection of low burden *Dirofilaria immitis* (heartworm) in dogs and cats. *Parasitology Research* (2018) 117:31–34
2. Masaya Naito (Shoku-kan-ken), Gen Kenoshita, G., Shimazaki, Y. Efficacy confirmation study of 6% topical formulation of Selamectin (Evicto®, Virbac) against Heartworm (*Dirofilaria immitis*) in cats. Data on file (2021).
3. Masaya Naito, M., Kenoshita, G., Shimazaki, Y. Efficacy confirmation study of 6% and 12% topical formulation of Selamectin (Evicto®, Virbac) against Heartworm (*Dirofilaria immitis*) in dogs. Data on file (2021).





I-16. IS IT TERMINAL? MEDICAL TREATMENT OF CAVAL SYNDROME

Kalinov, T.¹

¹Vitalis Veterinary clinic, Bulgaria, 4000, drkalinov80@gmail.com

Keywords: caval syndrome, heartworms, slow kill, pulmonary hypertension

The most severe devastating and life-threatening complication of heartworm disease is the caval syndrome! In the face of severe pulmonary hypertension, a part or entire worm burden migrates in the region of tricuspid valve and right atrium. The worms, usually attached to the tricuspid valves apparatus, moves with opening and closing of the valve. They destroy the red blood cells and predispose to thrombus formation. The best option is surgical extraction of the worms through jugular vein. Special equipment, skills and cost of the procedure are limitation factors. The patients are usually in bad condition and the risk from anesthesia is bigger. In this clinical case, I successfully manage to use medical therapy to stabilize and treat a dog with caval syndrome

HISTORY. Bulit is 10 years old, male, intact, Bulgarian shepherd dog. Regularly vaccinated and deworming. For several months he has started to lose weight, has become lethargic and he has exercise intolerance and occasional coughing. The owners thought that these are geriatric signs. Several days before examination he stopped eating and drinking and could not stay on his legs.

CLINICAL EXAMINATION. On the presentation the dog was cachectic and could not walk. Body temperature was 38.5 C. Mucous membrane were pale with CRT above 2 sec. Auscultation revealed harsh lung sounds, systolic heart murmur and stronger heart sounds on the right hemithorax with palpable heart thrill also on the right. Femoral pulse was fast and weak. Abdomen was slightly enlarged. CBC: WBC– 19.14 10⁹/l(6.00-17.00), NEU– 16.46 10⁹/l(3.00-12.00), PLT– 141 10⁹/l(165-500). Biochemistry revealed increased ALAT, ALP, BUN. Antigen test for heartworm was positive. On the echocardiography we found severely dilated right atrium, right ventricle and pulmonary arteries. There were heartworms attached to the tricuspid valve and moving through and from during systole and diastole. Left atrium and ventricle were collapsed and barely visible.

DIAGNOSIS. On the basis of these data we diagnosed class 4 heartworm disease with caval syndrome and severe pulmonary hypertension.

THERAPY AND FOLLOW UP. The owners have refused surgical removing of the worms. We have prescribed doxycycline– 10mg/kg/sid, topical imidacloprid with moxidectin(Advocate Bayer), and sildenafil– 1mg/kg/bid. A week later the dog has come for control examination. The general status was better, and echocardiography shown dilatation of the LV and LA but with worse systolic function probably from primary DCM. To the ongoing therapy we added pimobendan– 0.25mg/kg/bid, benazepril– 0.5 mg/kg/bid, prednisolone– 0.5 mg/kg/sid. Two weeks later, on the control examination we did not see heartworms in right heart, nor in the pulmonary artery. We stopped doxycycline after one month and continued with the other medications and monthly moxidectin. Six months after diagnosis the antigen test was negative. We continued with pimobendane, benazepril and sildenafil. The dog died two years later, at age of 12 from neoplasia of the spleen and lymph nodes, not histologically confirmed.





I-17. EVOLUTION OF THE CONTROL OF *DIROFILARIA IMMITIS* INFECTIONS, DURING MY LIFETIME

Guerrero, J.¹

¹Latin American Veterinary Conference, Lima, Peru, jorgegu1@hotmail.com

Keywords: Ivermectin, ELISA, prophylaxis

In the mid-sixties as I was a veterinary student in Lima, Peru *Dirofilaria immitis* as a parasite was hardly mentioned as no more than an occasional curious occurrence. Unfortunately, that is still the attitude of many of my colleagues in Latin America even now in 2022. By the early seventies as a graduate student in the USA the parasite was presented to us in depth. But at that time the alternatives to diagnose, prevent and treat heartworm disease were extremely limited. During the late seventies already as a professional in the pharmaceutical industry I explored the use levamisole as a microfilaricide with positive results. However, the other control tools available were minimal. But, at that time Bill Campbell and the research team of Merck and Co, Inc were already feverishly working with Ivermectin a wonder drug that revolutionized parasite control in general. I had the privilege to joint that team in the early eighties and experienced a golden age of parasitological research and development. First great development a once-a-month preventive treatment as Heartgard 30, then Heartgard Plus, then the development of the ELISA based diagnostic tests for canine heartworm by Idexx. A series of epidemiological studies of heartworm infections firs in dogs followed by several studies in cats in the USA, Latin America and Europe helped the veterinary profession to pay attention to this very important disease in pets. Other macrocyclic lactones followed and enhanced the veterinarian armamentarium against the most important canine disease in the USA. Nowadays the isoxazolines combined with macrocyclic lactones offer other dimensions on the parasite control duties of the veterinary profession. The discovery of the activity of Wolbachia on the pathology of heartworm infections was also a momentous step on the understanding of the host parasite relationship. What is coming? It is hard to predict but I hope to still witness further developments in the control of *D. immitis* infections in dogs and cats.





I-18. DIROFILARIA IMMITIS AND LOE/RESISTANCE IN EUROPE: IS IT HAPPENING?

Diakou, A.¹

¹Laboratory of Parasitology and Parasitic Diseases, School of Veterinary Medicine, Faculty of Health Sciences, Aristotle University of Thessaloniki, Greece, diakou@vet.auth.gr

Keywords: *Dirofilaria immitis*, macrocyclic lactones, resistance, monitoring

Dirofilaria immitis is the agent of heartworm disease, one of the most important parasitic diseases in veterinary medicine with zoonotic importance. Prevention in dogs and cats is achieved by the administration of products containing macrocyclic lactones (MLs), which target the third (infective) and fourth larval stages of the parasite. Although these drugs are very safe and highly effective, *D. immitis* strains resistant to MLs have been indisputably detected, at least around the Mississippi Delta region in the USA.

The resistance problem currently seems limited to those areas, and up to date, no confirmed case of MLs “Lack of Efficacy” (LOE) or resistance has been reported from Europe (1). However, because of the importance of *D. immitis* infection both in animals and in humans and considering the augmenting usage of endectoparasiticides with MLs as a potential selection pressure, it is important to remain vigilant for timely detection of any ML LOE/resistance in Europe. In this context, the question of the title “is it happening” should be posed and re-evaluated through the everyday veterinary practice.

Keeping this in mind, veterinary practitioners should get familiar with the simple steps they can follow, to keep a vigilant eye on possible/suspected LOE/resistance cases and contribute to their clarification/confirmation. A series of questions (2) investigating the history of an infection resembling resistant will be guiding and enlightening and includes the following: a) at what age prevention started, b) was there any testing gap, c) how compliant is the owner, d) what the preventive purchase history is, and e) are there chances that the preventive dose was divided to more animals in the household. In case suspicion persists after this investigation, or in case such data are unavailable, then a simple, in-clinic, microfilariae suppression test, i.e., number of microfilariae/ml of blood before, and 2-4 weeks after microfilaricidal administration, may be applied for assessing any resistant nature of the parasite. A count reduction of >95% suggests that the parasites are susceptible to MLs, and only a <75% reduction indicates a probability of resistant parasites, while values between <95% and >75% are linked with a minor likelihood of resistance (1).

For infections that remain LOE/resistance suspicious, further investigation on the molecular level would be of great value, for a timely and accurate surveillance of the problem. Specific single nucleotide polymorphism (SNPs) is being used in specialised Institutional laboratories, as markers of ML resistance, offering a basis for validation of clinically suspected resistant strains (3). However, there is clearly a need for a commercially available test that would be relatively simple and inexpensive, to be used in clinic or in routine diagnostic laboratories, so, companies that are active in the field of veterinary diagnostics should make an effort towards this end.

References

1. Diakou A, & Prichard RK. Concern for *Dirofilaria immitis* and macrocyclic lactone Loss of Efficacy: Current situation in the USA and Europe, and future scenarios. *Pathogens*. 2021 10(10), 1323.
2. Moorhead AR, Evans CC, Kaplan RM. A diagnostic algorithm for evaluating cases of potential macrocyclic lactone-resistant heartworm. *Parasit & Vectors*. 2017 10 (Suppl. S2), 479.
3. Ballesteros C, Pulaski CN, Bourguinat C, Keller K, Prichard RK, Geary TG. Clinical validation of molecular markers of macrocyclic lactone resistance in *Dirofilaria immitis*. *Int J Parasitol Drugs Drug Resist*. 2018 8, 596–606.





I-19. EVALUATION OF THE ADULTICIDAL EFFICACY BASED ON DIFFERENT FORMULATIONS OF MOXIDECTIN COMBINED WITH DOXYCYCLINE IN DOGS WITH HEARTWORM DISEASE

Ciuca L.¹, Vismarra A.², Constanza D.¹, Di Loria A.¹, Meomartino L.¹, Ciaramella P.¹, Cringoli G.¹, Genchi M.², Rinaldi L.¹, Kramer L.²

¹Department of Veterinary Medicine and Animal Production University of Naples Federico II, Via Federico Delpino 1, 80137 Naples, Italy; lavinia_vet1@yahoo.com

² Department of Veterinary Medicine Sciences, University of Parma, via del Taglio, 10, 43126 Parma, Italy

Keywords: oral, topical and injectable moxidectin, heartworm disease

Dirofilaria immitis is a vector-borne filarial nematode that causes canine heartworm disease (HWD) in many areas of the world (Genchi and Kramer, 2020). There are several studies that have reported a successful adulticide treatment based on a combination of macrocyclic lactones and doxycycline against *D. immitis* in dogs (Genchi et al., 2019; Vörös et al., 2022). However, there is only one report on the efficacy of extended-release injectable moxidectin combined with doxycycline in naturally infected dogs, in which 90.0% of the dogs were free of adult worms (Alberigi et al., 2020). Moreover, there is no data regarding the evaluation for adulticidal efficacy of oral moxidectin combined with doxycycline. Therefore, the study aimed to evaluate the adulticide effect of oral, topical and extended-release injectable formulations of moxidectin when combined with doxycycline in dogs naturally infected with *D. immitis* from a shelter located in southern Italy. A total of 30 dogs with naturally acquired *D. immitis* infection were allocated at random into three treatment groups (10 dogs for each group) and treated with the following moxidectin formulations: oral moxidectin (G1) once a month for 9 consecutive months, topical moxidectin (G2) once a month for 9 consecutive months and extended release moxidectin injectable (G3) at enrolment and again at 6 months (Day 180). All treatment groups received doxycycline for the first 30 days. Blood samples were collected each month for nine months, in order to evaluate the microfilarial concentration in 1 ml (mff/ml) of blood with the modified Knott's test and the circulating antigens using PetChek® HTWM PF (IDEXX, USA). Moreover, a clinical scoring system was employed for each dog enrolled in the study based on thoracic radiography and cardiac ultrasound (CU) exams performed at Day -15 (before treatment) and at Day 180. Results from the present study showed that there was a clear reduction of antigen concentration for all treatment groups, beginning as early as Day 30. At Day 270, 9/10 dogs (90.0%) from G1, 6/10 dogs (60.0%) from G2 and 8/10 dogs (80.0%) from G3 had at least 2 consecutive negative tests. Improvement of radiographic alterations was observed in all treatment groups, and almost all dogs were cleared of pulmonary abnormalities by six months from the beginning of treatment (p-value=0.000). Cardiac ultrasound examination showed a progressive improvement of cardiac function in a limited number of animals (4/30). In conclusion, the combination of moxidectin and doxycycline is effective in eliminating microfilariae and adults of *D. immitis*. However, the injectable moxidectin resulted to be more effective than the oral and topical formulations.

References

1. Genchi C, Kramer LH. The prevalence of *Dirofilaria immitis* and *D. repens* in the Old World. *Vet Parasitol*, 2020 280:108995. PMID: 32155518.
2. Genchi M, Vismarra A, Lucchetti C, Viglietti A, Crosara S, Gnudi G, Quintavalla C, Schaper R, Kramer L. Efficacy of imidacloprid 10%/moxidectin 2.5% spot on (Advocate®, Advantage Multi®) and doxycycline for the treatment of natural *Dirofilaria immitis* infections in dogs. *Vet. Parasitol*. 2019, 273, 11–16.
3. Vörös K, Becker Z, Kónya R, Arany-Tóth A, Farkas R. Application of Moxidectin and Ultrasound-Aided Injection of Melarsomine During the American Heartworm Society Recommended Treatment Protocol in *Dirofilaria immitis* Infected Dogs. *Vector Borne Zoonotic Dis*. 2022, 22, 382-390.
4. Alberigi B, Fernandes JI, Paiva JP, Mendes-de-Almeida F, Knackfuss F, Merlo A, Labarthe N. Efficacy of semi-annual therapy of an extended-release injectable moxidectin suspension and oral doxycycline in *Dirofilaria immitis* naturally infected dogs. *Parasit. Vectors*. 2020, 13, 503.





I-20. SAFETY OF ORAL AFOXOLANER FORMULATED WITH OR WITHOUT MILBEMYCIN OXIME IN HOMOZYGOUS MDR1 DEFICIENT COLLIE DOGS

Drag, M.¹, Tielemans, E.¹, Mitchell, E.¹

¹Boehringer Ingelheim Animal Health, loic.antoine@boehringer-ingelheim.com

Keywords: MDR1 deficient dog; afoxolaner; milbemycin oxime; safety.

An important proportion of collie dogs and other herding type canine breeds are deficient in P-glycoprotein, when mutant for its coding MDR1 gene [1,2]. P-glycoprotein is a plasma membrane efflux pump expressed in several tissues of mammals, and namely an essential component of the blood brain barrier for the protection of neurones from circulating xenobiotic molecules [3,4]. Afoxolaner, an arthropodicide compound of the isoxazoline class is available for dogs as an ectoparasiticide medicine (NexGard[®]), and as an endectoparasiticide medicine in combination with milbemycin oxime, a macrocyclic lactone (NexGard[®] Spectra). Little is known about isoxazoline interactions with P-glycoprotein, while macrocyclic lactones are well known P-glycoprotein substrates that may cause neurotoxicity in MDR1 deficient dogs [5]. The tolerances to a 3.8 multiple of the maximum NexGard[®] (afoxolaner alone) label dose, to a 4.7 multiple of the maximum NexGard[®] Spectra (afoxolaner and milbemycin oxime) label dose, and to an identical dose of milbemycin oxime administered alone were studied in MDR1 deficient collie dogs. No significant adverse reaction was observed in any dog treated with afoxolaner, alone or in combination with milbemycin oxime. Some mild and transient neurological signs attributed to macrocyclic lactone toxicity were observed in dogs treated with milbemycin oxime only. The studies demonstrated a high level of tolerance to oral afoxolaner, alone or in combination with milbemycin oxime, in homozygous MDR1 deficient dogs.

References

1. Mealey KL, Meurs KM. (2008). Breed distribution of the ABCB1-1Delta (multidrug sensitivity) polymorphism among dogs undergoing ABCB1 genotyping. *J Am Vet Med Assoc.* 2008 Sep 15;233(6):921-4. doi: 10.2460/javma.233.6.921. PMID: 18795852
2. Neff MW, Robertson KR, Wong AK, et al. (2004). Breed distribution and history of canine mdr1-1Delta, a pharmacogenetic mutation that marks the emergence of breeds from the collie lineage. *Proceedings of the National Academy of Sciences of the United States of America.* 2004 Aug;101(32):11725-11730. DOI: 10.1073/pnas.0402374101. PMID: 15289602; PMCID: PMC511012
3. Schinkel AH, Mol CA, Wagenaar E, van Deemter L, Smit JJ, Borst P. Multidrug resistance and the role of P-glycoprotein knockout mice. *Eur J Cancer.* 1995 Jul-Aug;31A(7-8):1295-8. doi: 10.1016/0959-8049(95)00130-b. PMID: 7577039
4. Mealey KL. (2008). Canine ABCB1 and macrocyclic lactones: heartworm prevention and pharmacogenetics. *Vet Parasitol.* 2008 Dec 10;158(3):215-22. doi: 10.1016/j.vetpar.2008.09.009. Epub 2008 Sep 7. PMID: 18922637
5. Paul AJ, Hutchens DE, Firkins LD, Borgstrom M. Dermal safety study with imidacloprid/moxidectin topical solution in the ivermectin-sensitive collie. *Vet Parasitol.* 2004 May 26;121(3-4):285-91. doi: 10.1016/j.vetpar.2004.03.005. PMID: 15135868.





I-21. DIROFILARIA IMMITIS EPIDEMIOLOGY AND THERAPY RELATED PROBLEMS IN SOUTH AMERICA

Labarthe, N.¹

¹ PPGBios/ Fundação Oswaldo Cruz and Universidade Federal Fluminense, inhalabarthe@gmail.com

Keywords: Tropical treatment; Moxidectin; Macrocytic Lactones; Doxycycline

Dirofilaria immitis is a parasite that affects dogs and cats in South America. This mosquito transmitted worm has been detected in ten of the twelve countries of South America (SA). The only country where surveys have been conducted and no infected dog could be detected is Chile. There are no reports for Uruguay and Paraguay. An overall heartworm infection frequency, except Chile, shows a range of 4.8 to 26%. Most countries have limited information with only one or two reports published. Therefore, considering that Brazil represents almost half of the SA territory and that there are plenty of reports from different areas of the Country, details will be presented using Brazil as a model. In the Amazon states, where floods are frequent, humidity and temperature are high and the natural environment is abundant, there are many infected dogs. Along the oceanic coast there are many sites where heartworm affects over 50% of the canine population. In these areas, the highest prevalence occurs along sandbanks and salt marsh lagoons. This distribution suggests that the most efficient vectors are sylvatic or salt marsh mosquitos. Cats are also found infected in SA, with reported prevalence of 13% of the canine. SA is a large and diverse area where many domestic dogs range free and where there are many wild canids living in the natural environment that are rich sources of microfilariae for the mosquitoes. This scenery added to the low income of most of the local human population that results in poorly kept pets, represent an uncouncted risk for all susceptible hosts. In spite of the high number of infected well cared for pets in the area, there is no registered adultice therapy in the marketplace of any of the twelve countries of SA. This has put Veterinarians in a hard position. Different countries market different chemoprophylactic products based on macrocytic lactones, most countries market point of care tests to detect the infection, but not unfrequently veterinarians don't recommend prevention, or the owners don't comply with the recommendation. In this scenery everyone loses. Pets get sick or even die of a preventable disease, owners suffer, and veterinarians lose profits and gain bad reputation. Although there is no adulticide product recommended by the American Heartworm Society in SA, there is plenty of preventives in the different markets. In a reality that units many infected dogs and no adultice treatment available, some treatment had to be implemented. Knowing that macrocytic lactones eliminate infective larvae, different ways of using these molecules were tested. When doxycycline was shown to interfere with worms' fitness, it did not take long for veterinarians to test the associations of doxycycline with macrocytic lactones. Currently, in Brazil the most used adulticide therapy is the association of moxidectin with doxycycline. This may be done using the topic moxidectin product or the parenteral moxidectin product. Either the topical or the parenteral moxidectin in association with doxycycline were shown to be efficacious. Different doses and timing is what we have been calling Tropical treatment.





I-22. CURRENT DISTRIBUTION AND EXPANSION OF ANGIOSTRONGYLOSIS

Oehm A.W.¹, Schnyder M.¹

¹Institute of Parasitology, Vetsuisse Faculty, University of Zurich, Winterthurerstrasse 266 A, 8057 Zurich, Switzerland, andreaswerner.oehm@uzh.ch

Keywords: *Angiostrongylus vasorum*, epidemiology, Europe, wildlife reservoir, spreading pattern.

The history of *Angiostrongylus vasorum* in Europe has been characterised by a patchy geographical distribution with locally high endemicity. In the past few decades however, the parasite has shown an incredible capacity to successfully establish itself in previously non-endemic areas, including Central, Northern, and Eastern Europe as well as the Iberian Peninsula. Seroepidemiological studies in several countries throughout Europe have confirmed the presence of the parasite in regions previously considered to be free. This geographical expansion has been promoted by an intricate combination of drivers such as increasing populations of sylvatic reservoirs, urbanisation, locally changing climatic factors determining the presence of the gastropod intermediate host as well as more frequent movements and travelling of dogs. Studies in Switzerland, that can be considered representative for large areas within Europe, have shown that prevalences of *A. vasorum* have increased drastically particularly starting around the year 2000, reaching a regional prevalence of more than 80 % in foxes. This marked increase has been in association with accumulated cases of canine angiostrongylosis as foxes share recreational areas with dogs close to the urban environment and are known to shed enormous amounts of first larval stages. Importantly, red fox populations have been prospering after the eradication of terrestrial rabies in several countries in Central Europe and their abundance in urban areas is a crucial factor increasing contamination of the environment and hence infection of intermediate hosts and domestic dogs. The available data have evidenced the key position of the red fox in the transmission dynamics of *A. vasorum* being the main wildlife reservoir for *A. vasorum* in Europe and have improved our understanding of the increasing number of cases of canine angiostrongylosis.

Although the entirety of reasons for the fast and successful spread of *A. vasorum* in Europe has not been completely elucidated, dog movements may further drive the spread of this parasite across Europe. The geographical expansion of *A. vasorum* requires constant monitoring of the epidemiological situation as well as an increased awareness among local veterinarians and dog owners.





I-23. NEUROLOGICAL AND NEURORADIOLOGICAL ASPECTS OF DOGS AFFECTED BY *ANGIOSTRONGYLUS VASORUM*

Golini, L.¹

¹Neurology and Neurosurgery Section, Veterinary Teaching Hospital Faculty of Veterinary Medicine, University of Zurich, Winterthurerstrasse 260, 8057, Zurich (CH), lorenzo.golini@uzh.ch

Keywords: neurological signs, neuroanatomical localization, brain, spinal cord, magnetic resonance imaging

Angiostrongylus vasorum is a verminous parasitosis present almost worldwide. Main neurological signs has been described as uncommon as 1-2% up to 5 or 7%. In a review of 23 published papers between 1993 and 2021, the cumulative occurrence of neurological signs is as high as 21% (61 cases in a total population of 280 studied dogs). The main three neurological signs observed at presentation are: reduced mental status (20 dogs in 61 neurological affected dogs), cranial nerve deficits and proprioceptive ataxia (16 occurrences in 61 neurologically affected dogs), and seizures in 14 patients. Proprioceptive deficits have been noted in 16 dogs and spinal pain in 10 dogs. Cerebellar ataxia was noted in 2 dogs, vestibular ataxia described in 4 dogs, while a not better classified ataxia in 2 other dogs. Tetraplegia in 2 dogs, tetraparesis in 6 dogs, paraparesis in 3 dogs, paraplegia 3 dogs, and hemiparesis in 2 dogs. Neuroanatomical localization was compatible in 18 cases with a forebrain localization, followed by multifocal in 4 patient, and cerebellovestibular in 3 dogs. Neuroanatomical localization within the spinal cord was a T3-L3 myelopathy in 4 dogs, an C1-C5 myelopathy in 2 dogs, and a L4-S3 myelopathy in 2 dogs. Of 23 dogs, no data were available for better depict their neurological signs and neuroanatomical localization. Most of the patients had other extraneurological signs. Computer tomography scans and magnetic resonance scans are able to depict hemorrhagic changes within the brain or spinal cord. Intraaxial hemorrhages are commonly hyperattenuating in comparison to normal brain tissue in computed tomography, and hemorrhages in the epidural canal can cause spinal cord compression. Using MRI anatomical sequences (T1WI, T2WI) and sequences susceptible to paramagnetic substances (T2*, SWI) single or multiple intraaxial bleedings larger than 5 mm are commonly encountered. In case of anemesis of spontaneous bleeding, in case of clinical evidence of spontaneous bleeding or laboratoristic evidence of hyperfibrinolysis (altered ROTEM) or evidence of beta three peak (personal communication M. Caldin, 2020), cerebrospinal fluid collection should be avoided as matter of precaution. In the few published cases, eosinophilic pleocytosis is rarely described as much as rarely is described the observation of L1 larve of *Angiostrongylus vasorum* swimming freely in the cerebrospinal fluid. Suspected diagnosis of *Angiostrongylus vasorum* can be drawn from clinical data, and fresh fecal smear can be as accurate as 50% of the cases, while *Angiostrongylus vasorum* rapid test can be accurate as high as 70%. In our experience, most dogs with neurological signs tends to have L1 larvae in fecal fresh smears, and a positive Angiorapid test. Unfortunately, despite clinical suspected cases should be treated immediately, euthanasia or death is a common outcome. In our institution, prednisolone at anti-inflammatory dosage have been historically added to the fenbendazole in neurological patient to reduce the likelihood of severe SIRS. At the post mortem examination, signs of meningoencephalitis with evidence of larvae and eggs in the cerebral vasculature have been described, even in dogs without neurological signs.

References

1. Colombo M., et al. *Pathogens*. 2021 Oct 23;10(11):1372
2. Di Cesare et al., *Parasites & Vectors* 2015; 8:438
3. Bourque AC et al. *Journal of Veterinary Diagnostic Investigation*. 2008; 20(1):11-20.
4. Glaus TM., et al. *Schweiz Arch Tierheilkd* 2016; 158(10)





I-24. ADVANCES IN THE PATHOGENESIS OF CANINE ANGIOSTRONGYLOSIS

Oehm A.W.¹, Schnyder M.¹

¹Institute of Parasitology, Vetsuisse Faculty, University of Zurich, Winterthurerstrasse 266 A, 8057 Zurich, Switzerland, andreaswerner.oehm@uzh.ch

Keywords: *Angiostrongylus vasorum*, pathogenesis, cardiopulmonary alterations, bleeding, host-parasite interactions.

The pathogenesis leading to the diverse array of clinical signs in canine angiostrongylosis is only partially elucidated. *Angiostrongylus vasorum* and its clinical manifestations have been described as “a great imitator”: clinical signs may be classified into the most frequent respiratory symptoms, followed by bleeding and, occasionally, by neurological symptoms. These may be accompanied by several unspecific signs.

While verminous pneumonia, caused by eggs and larval stages of *A. vasorum* in the lung tissues, explains coughing and dyspnoea, the reasons for coagulopathies are less evident. Bleeding is observed in up to one third of dogs infected with *A. vasorum*. Multiple hypotheses have attempted to explain the onset of coagulation disorders.

Retrospective analysis of clinical patients with and without signs of bleeding indicated that hyperfibrinolysis and hypofibrinogenemia lead to hypocoagulability (2). Serum proteomic analyses of sera from experimentally infected dogs revealed 139 up- and downregulated proteins throughout the course of infection. Pathway enrichment disclosed that the complement pathway of coagulation, in particular the lectin part and the coagulation cascade, were affected by the parasite (3). The qualitative comparison with experimentally infected foxes revealed that the number of proteins with differential abundance increased with chronicity of infection foxes. Enriched pathways obtained from both in- and decreased proteins included among others ‘platelet degranulation’ and ‘haemostasis’, and indicated both activation and suppression of coagulation (4). It is yet of interest that despite some similarities with dogs, foxes appear to express a more adequate immunopathological response to *A. vasorum* infection and may hence be more tolerant to the parasite compared with dogs, facilitating persistent infections in foxes. These observations are supported by recent investigations on the pathological changes observed in the lungs of *A. vasorum* infected foxes corroborating the presence of a classic granulomatous pneumonia with excessive, diffuse invasion of macrophages and a large number of giant cells. However, in contrast to previous work in dogs, extensive fibrotic alterations could not be confirmed in foxes. Our findings imply a longer evolutionary host-parasite adaptation in foxes, which constitute a key wildlife reservoir. From the perspective of the parasite, recent deep proteomic characterisation of the sex-specific excretory-secretory products (ESP) and of cuticular surface proteins of *A. vasorum* determined a total number of 1069 ESP (944 female, 959 male) and 1195 (705 female, 1135 male) surface proteins. Among these, putative modulators of host coagulation such as von Willebrand factor type D domain protein orthologues, proteases and protease inhibitors and subunits have been identified (5). *In vitro* trials suggest that E/S proteins play a role, but that multiple interaction mechanisms, including host reaction, finally lead to coagulopathies. The recent findings essentially contribute to our understanding of the underlying pathomechanisms of canine angiostrongylosis and clarify potential key aspects of disease emergence.

References

1. Koch J, Willesen JL. 2009. Canine pulmonary angiostrongylosis: An update. *Vet J* 179, 348-359.
2. Sigrist NE, Hofer-Inteeworn N, Jud Schefer R, Kuemmerle-Fraune C, Schnyder M, Kutter APN. 2017. Hyperfibrinolysis and hypofibrinogenemia diagnosed with Rotational Thromboelastometry in dogs naturally infected with *Angiostrongylus vasorum*. *J Vet Intern Med* 31, 1091-1099.
3. Tritten L, Gillis-Germitsch N, Kockmann T, Schnyder M. Quantitative proteomics analysis of *Angiostrongylus vasorum*-induced alterations in dog serum sheds light on the pathogenesis of canine angiostrongylosis. 2021. *Sci Rep* 11 1:283; doi: 10.1038/s41598-020-79459-9.
4. Gillis-Germitsch N, Kockmann T, Kapel CMO, Thamsborg SM, Webster P, Tritten L, Schnyder M. 2021. Fox serum proteomics analysis suggests host-specific responses to *Angiostrongylus vasorum* infection in canids. *Pathogens* 10 11; doi: 10.3390/pathogens10111513.
5. Gillis-Germitsch N, Kockmann T, Asmis L, Tritten L, Schnyder M. 2021. *Angiostrongylus vasorum* excretory/secretory and surface proteins contain several putative interactors with host coagulation. *Front Cell Infect Microbiol* 11, doi.org/10.3389/fcimb.2021.753320.





I-25. HEARTWORM DISEASE. NOT JUST A HEALTH TOPIC FOR CATS AND DOGS. HOW TO BETTER MANAGE AND OPTIMIZE EARNINGS AND CUSTOMER MANAGEMENT

Costa, R.¹

¹Brazilian Veterinary Hospital Association, renato.costa@petcare.com.br

Keywords: heartworm, prevention, Brazil.

Brazil has one of the largest pet populations in the world and, as expected, a profitable market for this sector. The Brazilian pet market was among the four largest in the world in the last decade. More than the expressive pet population, what makes the Brazilian market strong is the relationship between Brazilians and their pets. The so called human-pet bond surprises when 72% of the Brazilians consider their pets as members of their families and 27% celebrate their birthdays. Despite this, the share of the pet market occupied by veterinary services is only 8%. That is, far below the 25% of the North American market, for instance. In Brazil, preventive veterinary medicine as a whole is very little explored by veterinarians, and canine heartworm is a good example of this. The state of Rio de Janeiro has the highest records of canine heartworm disease in Brazil and the region of Barra da Tijuca, a wealthy neighborhood, has significant numbers. In 1991, one year before the first heartworm preventive was made available in the country, 31% of dogs in this region were infected. Veterinarians started prescribing the preventive effectively and, by the year 2000, the prevalence had dropped to 1.93%. The perceived disappearance of heartworm made veterinarians complacent and the prevalence rose again to 21% in 2010. If there is no lack of studies and data showing the high prevalence of the disease in Barra da Tijuca. If there are several ways to prevent it. If the region of Barra da Tijuca has a high-income population. If the human-pet bond in Brazil is so strong. What could explain that a zoonotic preventable disease, potentially fatal for dogs can reach such alarming rates? When analyzing the percentages of dogs under ProHeart SR12 as a heartworm preventive, from 10 veterinary practices in Barra da Tijuca, we realized that the commitment of veterinarians to prevention can be decisive for client adherence. At Pet Care Animalia, where several measures are adopted for veterinarians to address the prevention of heartworm, in a period of 12 months of the 1287 dogs vaccinated against rabies, 1028 received administration of ProHeart SR12 (79.9%). In the other 9 clinics in the same region, in the same period, of the 7,410 vaccinated against rabies, only 2,180 received prevention for heartworm disease (29.4%). Revenue from prevention with ProHeart SR12 at Pet Care Animalia represents 4.2% of the clinic's total income. The profit margin of this service is around 60%. Therefore the prevention of heartworm is not only very important for the health of dogs and pet owners families but also for the health of veterinary practices.





Oral communications

O-1. DIROFILARIA IMMITIS IS NOT A NORTHERN ITALY PARASITE ANYMORE

Napoli, E.^a; De Benedetto, G.^a; Ciuca, L.^c; Bosco, A.^c; Lia, R.P.^d; Veneziano, V.^c; Otranto, D.^d; Rinaldi, L.^c; Brianti, E.^a

^aDepartment Veterinary Sciences, University of Messina, Messina, Italy, enapoli@unime.it

^cDepartment of Veterinary Science, University of Napoli, Napoli, Italy

^dDipartimento di Medicina Veterinaria, Università degli Studi di Bari, Valenzano, Italy

Keywords: *Dirofilaria immitis*; epidemiology; canine heartworm disease; Southern Italy.

Canine filarioses caused by *Dirofilaria repens* and *Acanthocheilonema reconditum* have been constantly reported as endemic in southern Italian regions, while *Dirofilaria immitis* is considered sporadic in these regions, and negligible its risk of transmission to dogs. However, in the last decade, the number of autochthonous cases or foci of *D. immitis* in dogs from southern regions increased significantly suggesting a new distribution pattern for this parasite. To provide more evidence to the southwards spread of *D. immitis* a cross-sectional multicentric survey on canine filarioses was carried out.

Owned and sheltered dogs from six southern regions (i.e., Lazio, Campania, Apulia, Basilicata, Calabria and Sicily) were included in the survey regardless their breed, attitude and/or gender. All the dogs were elder than 1 year and had no history or were not under preventative treatment against filarioses. A blood sample was collected from each included dog and analysed with Knott's test and, if positive, further tested using a *D. immitis* specific ELISA antigen test.

A total of 1987 dogs were enrolled in the survey. The overall microfilaremia prevalence was 17% (338/1987) being single-species infection (92.6%) more common than mixed (7.4%). Remarkably, *D. immitis* was the most frequent species with an overall prevalence of 11.4% (no. 227), followed by *D. repens* (no. 74, 3.7%) and *A. reconditum* (no. 12, 0.6%). Sheltered dogs were significantly more at risk for *D. immitis* ($\chi^2 = 163.3427$, $p < 0.00001$), and, in the same manner, mongrel dogs ($\chi^2 = 92.7365$, $p < 0.00001$) and animals housed in rural areas ($\chi^2 = 80.7429$, $p < 0.00001$) were more frequently infected by *D. immitis*.

The findings of the survey add more evidence to the spread of *D. immitis* infection through southern Italian regions and paradigm as the parasite can colonize new territories and threaten animal and human health slyly. Southern Italian regions should not be considered anymore as non-endemic for *D. immitis*. Practitioners and dogs' owners must be aware of this risk, and the adoption of effective strategies to protect dogs and control new infections should be promoted.

Acknowledgment: The study was partially founded by Boehringer Ingelheim A.H. Italia

Region	No. dogs	Positive (%)	<i>D. immitis</i> (%)	<i>D. repens</i> (%)	<i>A. reconditum</i> (%)
Sicily	607	103 (17.0)	52 (8.6)	40 (6.6)	10 (1.7)
Calabria	174	9 (5.2)	4 (2.3)	2 (1.2)	2 (1.2)
Basilicata	41	0 (-)	-	-	-
Apulia	417	195 (46.8)	163 (39.1)	21 (5.0)	0 (-)
Campania	598	27 (4.5)	4 (0.7)	11 (1.8)	0 (-)
Lazio	150	4 (2.7)	4 (2.7)	-	-
Total	1987	338 (17.0)	227 (11.4)	74 (3.7)	12 (0.6)





O-2. HAPLOTYPES OF *DIROFILARIA REPENS* FROM POLAND AND SELECTED COUNTRIES OF CENTRAL, NORTH-EASTERN EUROPE AND THE MIDDLE EAST, AN EVALUATION ON THE RELATION BETWEEN THE GENETIC DIVERSITY AND THE GEOGRAPHIC DISTRIBUTION

Alsarraf, M.¹; Baneth, G.²; Bogucka-Kocka, A.³; Ciuca, L.⁴; Dwużnik-Szarek, D.¹; Fuehrer, H.P.⁵; Kloch, A.⁶; Kołodziej, P.³; Levytska, V.^{7,9}; Mierzejewska, E.J.¹; Mihalca, A.D.⁸; Mushynskiy, A.⁷; Nachum-Biala, Y.²; Alsarraf, M.¹; Bajer, A.¹

1. Department of Eco-Epidemiology of Parasitic Diseases, Institute of Developmental Biology and Biomedical Sciences, Faculty of Biology, University of Warsaw, Miecznikowa 1, 02-096, Warsaw, Poland, m.alsarraf@student.uw.edu.pl
2. The Koret School of Veterinary Medicine, The Hebrew University of Jerusalem, P.O. Box 12, Rehovot 7610001
3. Chair and Department of Biology and Genetics, Medical University of Lublin, Chodźki 4A, 20-093 Lublin, Poland
4. Department of Veterinary Medicine and Animal Production, University of Napoli Federico II, Via Delpino 1 - 80137, Napoli (Italy)
5. Institute of Parasitology, Vetmeduni Vienna, Veterinaerplatz 1, 1210 Vienna, Austria
6. Institute of Functional Biology and Ecology, Univeristy of Warsaw, Miecznikowa 1, 02-096 Warszawa
7. Department of Infectious and Invasive Disease, Podillia State University, Shevchenko 12, 32316, Kamianets-Podilskiy, Ukraine
8. Department of Parasitology and Parasitic Diseases, University of Agricultural Sciences and Veterinary Medicine of Cluj-Napoca, Calea Manastur 3-5, Cluj-Napoca, 400372, Romania
9. Institute of Parasitology, Biology Centre CAS, Branišovská 1160/31, 370 05, České Budějovice, Czech Republic

Keywords: *Dirofilaria repens*, COI, NADH, ITS-1, Haplotype

Subcutaneous dirofilariosis is a fast-spreading infection of dogs, and occasionally of other carnivores and humans. Several factors contribute to its spread, including climate change, which facilitates development and survival of *Dirofilaria repens* in the mosquito vector. Movement/relocation of infected definitive hosts (dogs) from endemic regions to non-endemic regions is another possible cause of local emergence and the presence of wide variety of wild reservoirs of the parasite may also contribute to its spread.

The main aim of this study was to evaluate the genetic diversity of *D. repens* from different regions of Europe and to evaluate the spread of identified haplotypes and their geographic origin.

A total of 95 *D. repens* isolates were obtained from Central and Eastern Europe (Poland, Belarus, Ukraine, Austria, Romania), North-eastern Europe (Lithuania, Latvia, Estonia), Italy and Israel. All but two positive samples were obtained from dogs while one positive sample was obtained from an adult worm from a human case from the Lublin area in south-eastern Poland and one sample was obtained from *Anopheles plumbeus* from Austria.

Genetic diversity in *D. repens* isolates was evaluated by PCR amplification and sequencing of three genetic markers, including two mitochondrial (mtDNA) genes: the cytochrome c oxidase subunit I (COI) and dehydrogenase subunit I (NADH). Additionally, the genomic marker internal transcribed spacer 1 (ITS-1) was amplified and sequenced.

Alleles were differentiated based on sequence alignments by identifying Single Nucleotide Polymorphism (SNPs) using DnaSP and Mega X.

PopArt was used to construct a haplotype network including all identified haplotypes. Both mtDNA gene sequences (COI and NADH) were combined together for phylogenetic and network analyses.

Altogether 18 haplotypes (DR1-DR18) were identified in combined mtDNA markers among 95 analyzed samples.

Haplotype DR1 was the most common encompassing 66 isolates: 42 isolates from Poland (41 from dogs and one from a human), 13 from Lithuania, 4 from Latvia, 2 from Ukraine and 5 from Romania. All other haplotypes grouped around haplotype DR1 separated by 1-5 SNPs, forming a star-like shape. Haplotype DR2 was the second most common haplotype, formed by six isolates from Romania. Interestingly, haplotype DR3 was represented only by four isolates from Israel. The remaining 15 haplotypes were represented by 1-4 isolates of different origins.

Our study showed that only minor genetic diversity was found in *D. repens* since all isolates appear to have clustered in or branched out from haplotype DR1 with 1-5 SNP differences. The genetic diversity appears to be governed by geographic origin since isolates from neighbouring populations (countries) appear to share unique haplotypes while other populations that are geographically distant form individual haplotypes.





Country	Newly Endemic						Endemic				No Data	Total
	Poland	Poland (Human)	Lithuania	Latvia	Estonia	Austria	Italy	Romania	Israel	Ukraine	Belarus	
No. of isolates	41	1	18	6	1	2	3	12	4	5	2	95
Region	Central Europe	Central Europe	Baltic	Baltic	Baltic	Central Europe	Southern Europe	Central Europe	Middle East	Eastern Europe	Eastern Europe	

Table 1: Distribution of isolates by country of origin

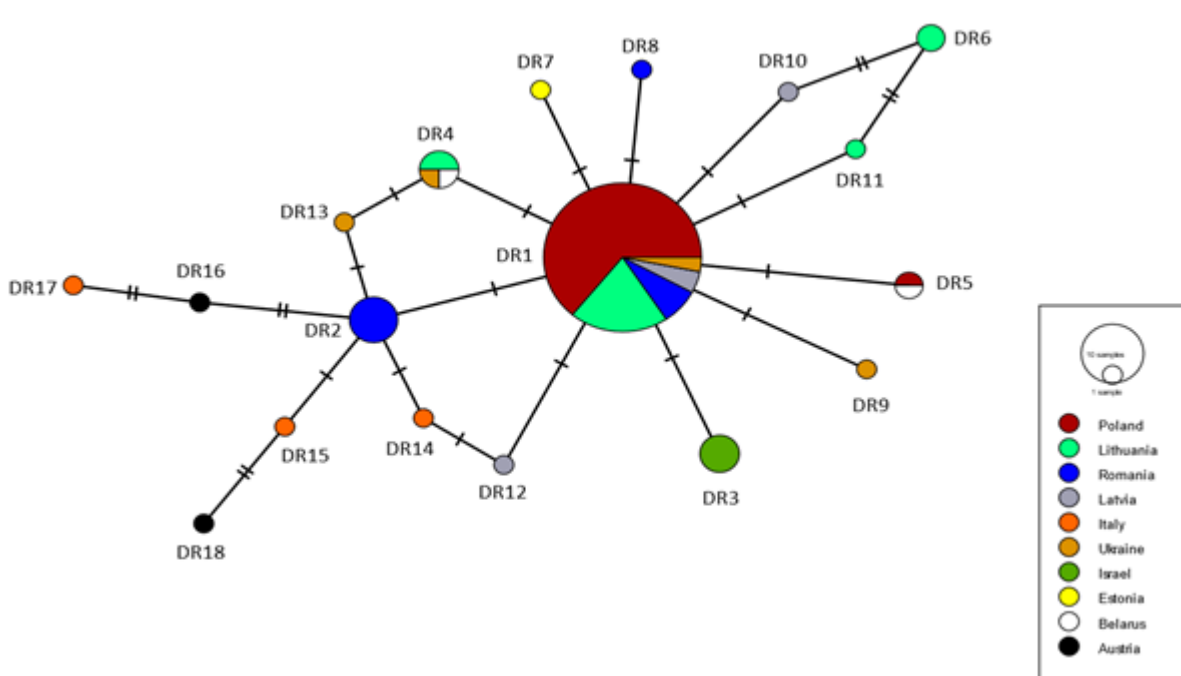


Figure 1: Median Spanning Network of mt double-locus sequence (COI and NADH) showing relationship between 18 delineated haplotypes

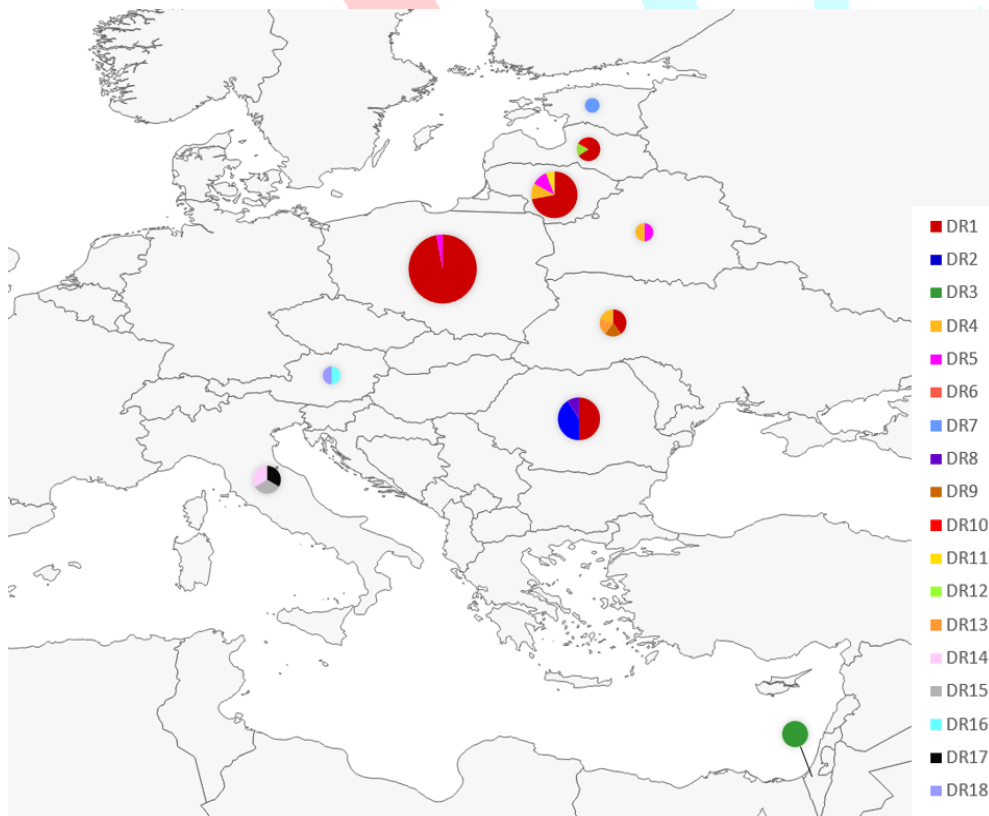


Figure 2: Geographic distribution of 18 mitochondrial haplotypes by country of origin. Size of pie charts is proportional to sample size.





O-3. ANALYSIS THROUGH ECOLOGICAL NICHE MODELLING OF THE CURRENT RISK OF DIROFILARIASIS TRANSMISSION IN IBERIAN PENINSULA (SPAIN AND PORTUGAL), AND ITS FUTURE PROJECTION UNDER CLIMATE CHANGE SCENARIOS

Rodríguez-Escobar, I.¹, Sánchez Agudo J.A., P.², Hernández Lambraño, R. E.², Montoya-Alonso, J.A.³, Carretón, E.³, Morchón, R.¹

¹Zoonotic diseases and One Health group, Laboratory of Parasitology, Faculty of Pharmacy, University of Salamanca, 37007, Salamanca, Spain. ivanrodriguez@usal.es

²Biodiversity, Human Diversity and Conservation Biology Research Group, University of Salamanca.

³Faculty of Veterinary Medicine, Research Institute of Biomedical and Health Sciences (UIBS), University of Las Palmas de Gran Canaria, Arucas, 35413, Las Palmas, Spain.

Keywords: Risk, *Dirofilaria*, climatic change, ecological niche modelling, Spain, Portugal.

Dirofilariosis is a vector-borne zoonotic disease caused by several species of the genus *Dirofilaria* spp. with *D. immitis* and *D. repens* being the most important. Canids and felids, both domestic and wild, are the main reservoirs. Their presence depends on environmental and bioclimatic factors that condition the presence of these vectors. In Spain there is a previous work where a simple model was developed using Geographic Information Systems, using three variables: temperature, rainfall and distribution of irrigated crops. Our objective is to analyse by means of Ecological Niche Modelling (ENM) the current risk of dirofilaria transmission in Iberian peninsula (Spain and Portugal), taking into account new factors and making a projection into the future. ArcGIS was used to process predictor variables (bioclimatic, distribution of surface and groundwater bodies, *Cx. pipiens* habitat, land use, biogeographical regions, vegetation layers, etc.) and presence of infected animals. The MaxEnt algorithm was used to develop NEMs for *Dirofilaria* spp. and *Cx. pipiens*. The highest risk of infection is in the southern and eastern provinces of the peninsula, with new areas appearing in southern Portugal and its coastal areas, as well as in the north of the peninsula. Furthermore, the risk of infection also increases in those inland areas with higher rainfall and higher soil humidity. The presence of irrigated land is also positively correlated with the presence of the disease. Finally, the 20- and 40-year projection according to climate change scenarios shows a clear potential increase in the risk of infection in Spain and Portugal. This methodological proposal is interesting from a One Health point of view, as it offers clear guidelines for the implementation of control measures to avoid the risk of infection in animals and humans.

References

1. Morchón R, Carretón E, González-Miguel J, Mellado-Hernández. I. Heartworm disease (*Dirofilaria immitis*) and their vectors in Europe – new distribution trends. *Front Physiol.* 2012; 3:196.
2. Simón L, Afonin A, López-Díez LI, González-Miguel J, Morchón R, Carretón E, Montoya-Alonso JA, Kartashev V, Simón F. Geo-environmental model for the prediction of potential transmission risk of *Dirofilaria* in an area with dry climate and extensive irrigated crops. The case of Spain. *Vet Parasitol.* 2014; Mar 1;200(3-4):257-64.
3. Mattsson BJ, Mateo-Tomás P, Aebischer A, Rösner S, Kunz F, Schöll EM, Åkesson S, De Rosa D, Orr-Ewing D, Bodega D, Ferrer M, Gelpke C, Katzenberger J, Maciorowski G, Mammen U, Kolbe M, Millon A, Mionnet A, Puente J, Raab R, Vyhnal S, Ceccolini G, Godino A, Crespo-Luengo G, Sanchez-Agudo JA, Martínez J, Iglesias-Lebrija JJ, Ginés E, Cortés M, Deán JI, Calmaestra RG, Dostál M, Steinborn E, Viñuela J. Enhancing monitoring and transboundary collaboration for conserving migratory species under global change: The priority case of the red kite. *J Environ Manage;* 2022 Sep 1; 317:115345.





O-4. SURVEY OF ITALIAN VETERINARY PRACTITIONERS ON *DIROFILARIA IMMITIS* AND *D. REPENS*: SECOND EDITION

Genchi, M.¹, Kramer, L.¹, Vismarra, A.¹, Rinaldi, L.², Venco, L.³

¹ Department of Veterinary Science, University of Parma, Parma, Italy, marco.genchi@unipr.it

² Department of Veterinary Medicine and Animal Production, University of Naples “Federico II”, Naples, Italy

³ Ospedale Veterinario Città di Pavia, Pavia, Italy

Keywords: *Dirofilaria immitis*, *Dirofilaria repens*, Dog, Cat, Questionnaire, Epidemiology

In 2018, an online questionnaire was conducted to evaluate practitioners' knowledge on dirofilariosis (*D. immitis*, *D. repens*) in dogs and cats (Genchi et al., 2019). Four years later, we have decided to re-propose the survey in order to update the data and evaluate an improvement in veterinarians' awareness about dirofilariosis. In March 2022, an electronic questionnaire was sent to all Italian veterinary facilities (surgeries, clinics, hospitals and public facilities). In addition, in collaboration with Zoetis Italia S.r.l., the questionnaire was advertised through the network of their sales representatives and social networks (i.e Instagram and Facebook). The 34 questions of the survey focused mainly on where the facilities were located, and on diagnosis, prevention, and treatment commonly used for *D. immitis* and *D. repens* in dogs and cats. In addition, practitioners were asked if they knew of guidelines for dirofilariosis. The questionnaire was sent to 3449 veterinary facilities. The overall response rate was 22%. Data showed that 27% of facilities reported only infections of *D. immitis*, 4% only of *D. repens*, 17% mixed infections and 51% no cases of either parasite in the last year. *D. immitis* infections were observed especially in northern and central Italy. However, many regions of the south and the islands (Sicily and Sardinia) also reported heartworm infections. *D. repens* was fairly evenly distributed throughout Italy and mainly as co-infections with *D. immitis*. The most frequent diagnostic method used in dogs was the Ag test (23%) followed by the fresh blood smear together with the ag test (22%) and the aid of a diagnostic laboratory (8%). Knott's test together with ag test, thoracic radiology and ultrasound examination were used by 3% of the facilities. The most frequent diagnostic techniques used for *D. repens* in dogs were: external diagnostic laboratory (29%), fresh blood smear and skin biopsy (11%), knott's test (7%). The most frequent diagnostic technique used for *D. immitis* in cats were: external diagnostic laboratory (26%), Ag test (23%) and fresh blood smear (8%). For treatment of canine heartworm infection, more than 28% used ivermectin + doxycycline or moxidectin+ doxycycline (27%), while more than 24% used only melarsomine. Prevention was started in the dog in April (32%) - March (18%) and ended in november (35%), while 15% treated all year. Finally, more than 46% knew the ESCCAP Guideline, 38% knew the AHS Guideline, while 34% knew the ESDA Guideline. Our data showed that *D. immitis* and *D. repens* are distributed in most of the Italian provinces. Furthermore, the diagnosis is often underestimated and relies mainly on serology alone. This type of study can be considered a good starting point for the development of clearer guidelines proposed by scientific societies, together with the need of a more widespread diffusion and, not less important, a useful and rapid method to have updated risk maps.

References

1. Genchi M, Rinaldi L, Venco L, Cringoli G, Vismarra A, Kramer L. *Dirofilaria immitis* and *D. repens* in dog and cat: A questionnaire study in Italy. *Vet Parasitol.* 2019 Mar;267:26-31.





O-5. SPREADING OF *DIROFILARIA IMMITIS* IN SOUTHERN ITALY: A THREAT TO HUMAN AND ANIMAL HEALTH

Gabrielli, S.¹; Mendoza-Roldan, J.A.²; Napoli, E.³; Iatta, R.²; Brianti, E.³; Otranto, D.²

¹Department of Public Health and Infectious diseases, Sapienza University of Rome, Rome, Italy; simona.gabrielli@uniroma1.it

²Department of Veterinary Medicine, University of Bari, Valenzano, Italy;

³Department of Veterinary Sciences, University of Messina, Messina, Italy.

Keywords: *Dirofilaria immitis*; human; animals; Italy; One Health approach

In the past few decades, many of the arthropod-borne diseases have changed their distribution emerging in previously free areas driven by various anthropogenic constituents, such as environmental factors, climatic changes, increased movements of pets traveling with their owners, animal rehoming, and genetic factors (e.g., host adaptation and susceptibility). The changing in the epidemiology of *Dirofilaria immitis* in Italy is paradigmatic of this, since historically, it was considered endemic in northern regions (1), though an increasing number of autochthonous cases have been recently reported in southern areas, where *Dirofilaria repens* was traditionally considered endemic (2).

Here we reported the results of a multidisciplinary survey conducted in southern Italy (Sicily) aiming to describe the occurrence and the distribution of *Dirofilaria* spp. in dogs, cats and humans as well as in their mosquito vectors. The study was performed in Linosa and Lampedusa, two small islands of the Pelagie Archipelago, which represent a confined/close environment where many interactions among humans, dogs and cats occur.

Human blood samples (n=346) were collected from healthy individuals along with blood from 158 dogs and 46 cats living in the islands, while mosquito sampling was performed only in the island of Linosa. Human sera were tested by a home-made ELISA (3), while genomic DNA was extracted from blood samples of dogs and cats, and from mosquitoes to molecularly detect the parasites (4). Fed mosquito specimens were also submitted to blood-meal identification by PCR (5).

Despite none of the individuals involved in the study reported specific symptoms of dirofilariosis, anti-*Dirofilaria* antibodies were detected in 19.4% of the subjects, i.e., 7.8% positive to *D. immitis*, 15.9% to *D. repens*, and 4.3% to both species. Analyzing seroprevalence data separately for each species and island, *D. repens* resulted significantly more prevalent in Lampedusa than in Linosa (p<0.0001), while no significant differences were noted about *D. immitis* prevalence in the two islands (p=0.968). Accordingly, *D. immitis* was identified in 58.9% of dogs and 17.6% of cats from Linosa while *D. repens* in 7.9% of dogs from Lampedusa. Finally, one specimen of *Aedes albopictus* tested molecularly positive to *D. immitis* and human DNA was detected by blood meal identification.

Overall, the present study demonstrates the human exposure to both *Dirofilaria* species in Linosa and Lampedusa islands. Particularly, the higher seroprevalence of *D. immitis* in Linosa could be linked to the hyperendemic status of canine heartworm in the island where about 60% of the dogs were infected. Furthermore, the occurrence of *D. immitis* in *Ae. albopictus*, a generalist zoophilic feeder and the identification of human blood source, confirms the role of this mosquito species in the transmission of *Dirofilaria* among animals and humans, thus representing a potential risk for people living on the island. Data herein presented, confirm the spreading of *D. immitis* in previously non-endemic areas of southern Mediterranean region and its circulation among animals, humans and vectors; also, the multidisciplinary approach of this survey underlines the importance of the One Health concept in defining the epidemiological scenario of zoonotic parasites.

References

1. Capelli G, Poglayen G, Bertotti F, Giupponi S, Martini M. The host-parasite relationship in canine heartworm infection in a hyperendemic area of Italy. *Vet Res Commun.* 1996;20(4):320-330.
2. Mendoza-Roldan J, Benelli G, Panarese R, Iatta R, Furlanello T, Beugnet F, Zatelli A, Otranto D. Leishmania infantum and Dirofilaria immitis infections in Italy, 2009-2019: changing distribution patterns. *Parasit Vectors.* 2020 Apr 15;13(1):193.
3. Simón F, Siles-Lucas M, Morchón R, González-Miguel J, Mellado I, Carretón E, Montoya-Alonso JA. Human and animal dirofilariosis: the emergence of a zoonotic mosaic. *Clin Microbiol Rev.* 2012 Jul;25(3):507-44.
4. Otranto D, Brianti E, Dantas-Torres F, Weigl S, Latrofa MS, Gaglio G, Cauquil L, Giannetto S, Bain O. Morphological and molecular data on the dermal microfilariae of a species of Cercopithifilaria from a dog in Sicily. *Vet Parasitol.* 2011 Dec 15;182(2-4):221-9.
5. González E, Jiménez M, Hernández S, Martín-Martín I, Molina R. Phlebotomine sand fly survey in the focus of leishmaniasis in Madrid, Spain (2012-2014): seasonal dynamics, Leishmania infantum infection rates and blood meal preferences. *Parasit Vectors.* 2017 Aug 1;10(1):368.





O-6. VECTOR-BORNE PARASITES *DIROFILARIA REPENS* AND *BABESIA CANIS*: HEMATOLOGICAL PARAMETERS AND PROFILE OF IMMUNE RESPONSE IN NATURALLY INFECTED AND CO-INFECTED DOGS

Wężyk D.¹, Romańczuk K.², Rodo A.³, Kavalevich D.¹, Bajera A.¹

¹Department of Parasitology, Institute of Zoology, Faculty of Biology, University of Warsaw, 1 Miecznikowa Street, 02-096, Warsaw, Poland. d.wezyk@student.uw.edu.pl

²Department of Pathology and Veterinary Diagnostics, Warsaw University of Life Sciences- SGGW, 159c Nowoursynowska Street, 02-766 Warsaw, Poland.

³Lab-Wet, Veterinary Diagnostic Laboratory, ul. Wita Stwosza 30, 02-661 Warsaw, Poland.

Keywords: *Babesia canis*, blood parameters, *Dirofilaria repens*, immune response.

Co-infection of *Dirofilaria repens* and *Babesia canis* are rarely reported in the literature and there is very limited knowledge of their impact on canine health. Central Poland is endemic for both parasites which poses a risk of co-infection in dogs.

To evaluate the impact of co-infection of *B. canis* and *D. repens* on canine health, four groups of dogs were examined: healthy dogs, dogs infected with *B. canis*, dogs infected with *D. repens* and dogs co-infected. Blood parameters indicative of anemia, kidney and liver damage were statistically analyzed. Additionally, expression levels of immune response genes were determined and compared to assess the type of immune response in single- and co-infections.

In dogs infected with *D. repens*, no major alterations in blood parameters were observed. Dogs infected with the *B. canis* suffered from anemia, kidney and liver insufficiency. In contrast, dogs with co-infection with *D. repens* and *B. canis* showed milder alternation in blood biochemical parameters associated with liver (AST, ALT, AP activity) and kidney (serum urea and creatinine levels) dysfunction compared to dogs infected only with *B. canis*. The expression of genes associated with Th1 (STAT4 and IFN- γ) and Th2 (STAT6, GATA3, IL-10, IL-13) immune response and SOCS3 gene was determined. For this analysis, dogs infected with *B. canis* were divided into 2 groups – ‘Babesia 1’ (mild babesiosis), ‘Babesia 2’ (severe babesiosis). In dogs infected with *D. repens*, expression of all tested factors except INF- γ was observed. In ‘Babesia 1’ dogs the highest expression of GATA3 and IL-10 was detected, while in ‘Babesia 2’ - INF- γ , IL-10 and SOCS3. The expression of IL-13 was predominant in dogs infected with *D. repens*, and the expression of STAT6 and IL-10 in dogs with co-infection. In conclusion, no major deviations in blood parameters were found in dogs infected with *D. repens*. Interestingly, the values of biochemical parameters in dogs with co-infection were closer to those of healthy dogs than those solely infected with *B. canis* suggesting milder course of babesiosis in these animals. Dogs infected with *B. canis* showed expression of Th1 and Th2 immune response factors, whereas dogs infected with *D. repens* expressed Th2 immune response factors. Features of Th1 or Th2 response were observed in *B. canis* and *D. repens* co-infected dogs. However, a Th2 immune response appears to predominate in co-infection.

Acknowledgements. The study was funded by the National Science Center (NCN) OPUS grant no. 2017/27/B/NZ6/01691.





O-7. ANGIOGENIC PROCESS AS A SURVIVAL MECHANISM PRODUCED BY EXCRETORY/SECRETORY ANTIGENS OF DIROFILARIA IMMITIS ADULTS WORMS AND CUTICLE PROTEINS

Pérez Rodríguez, P.¹, Cardona-Machado, C. D.¹, Alarcón-Torrecillas, C.², Pericacho, M.², Rodríguez-Escolar, I.¹, Carretón, E.³, Montoya-Alonso, J.A.³, Morchón, R.¹

¹Zoonotic diseases and One Health group, Laboratory of Parasitology, Faculty of Pharmacy, University of Salamanca, 37007, Salamanca, Spain. rmorgar@usal.es

²Department of Physiology and Pharmacology, Biomedical Research Institute of Salamanca (IBSAL), University of Salamanca, Salamanca, Spain.

³Internal Medicine, Faculty of Veterinary Medicine, Research Institute of Biomedical and Health Sciences (IUIBS), University of Las Palmas de Gran Canaria, Las Palmas de Gran Canaria, Spain.

Keywords: HUVEC, *Dirofilaria repens*, endothelial cells, angiogenesis

Angiogenesis is a process in which new blood vessels are formed due to obstructive inflammatory processes or hypoxia where migration, growth and differentiation of endothelial cells are particularly important. These stimuli are present in heartworm infections, where *D. immitis* excretory/secretory antigens are related to the vasodilator response, facilitating parasite survival. Furthermore, in an in vitro model using dog microvascular endothelial cells, they observed that the somatic antigen of *D. immitis* adult worms produced a proangiogenic effect. Therefore, the aim was to analyze the capacity of excretory/secretory antigens of *Dirofilaria immitis* adult worms and cuticle proteins to modify the expression of angiogenic factors and trigger the formation of pseudocapillaries (tube-like structures) in an "in vitro" model of human endothelial cells (HUVECs). HUVECs were treated with 1 ug/ml of *Dirofilaria immitis* excretory/secretory antigens (DiES), cuticle proteins (Cut), VEGF, DiES + VEGF and Cut+VEGF. Non-stimulated cells were used as controls in the same conditions. Angiogenic factors (VEGF-A, VEGFR1, VEGFR2, m- and s-Endoglin) concentration were measured using a commercial ELISA. Proliferation was analyzed by determining the number of cells by staining nuclei with MTT. Cell migration was assessed by quantifying the percentage of wound closure in the healing assay. The capacity of pseudocapillary formation was evaluated analyzing endothelial cell tube formation, the cells and intercellular junctions, and the morphological changes on Matrigel[®] cell cultures. The results showed that DiES and Cut and VEGF did not produce any cytotoxic effect. The effect of DiES and Cut +VEGF produced a significant increase in mEndoglin and VEGFR2 (proangiogenic) ($p < 0,005$), increase in pseudocapillary formation ($p < 0.001$), in cell migration ($p < 0.001$) and in cell proliferation ($p < 0.005$) compared to the other stimuli and control cells in HUVECs. Excretory/secretory antigens of *Dirofilaria immitis* adults worms and cuticle proteins act as a proangiogenic stimulant in the angiogenic process (formation of new vessels) by stimulating proangiogenic molecules, as well as cell migration and proliferation and the formation of pseudocapillaries in HUVECs as a means of survival.

References

1. Morchón R, Carretón E, González-Miguel J, Mellado-Hernández. I. Heartworm disease (*Dirofilaria immitis*) and their vectors in Europe – new distribution trends. *Front Physiol.* 2012; 3:196.
2. Morchón R, González-Miguel J, Mellado I, Velasco S, Rodríguez-Barbero A, Simón F. Adult *Dirofilaria immitis* excretory/secretory antigens upregulate the production of prostaglandin E2 and downregulate monocyte transmigration in an "in vitro" model of vascular endothelial cell cultures. *Vet Parasitol.* 2012; 170(3-4), 331–335.
3. Zueva T, Morchón R, Carretón E, Montoya-Alonso JA, Santana A, Bargues Castelló, MD, Mas-Coma S, Rodríguez-Barbero A, Simón F. Angiogenic response in an in vitro model of dog microvascular endothelial cells stimulated with antigenic extracts from *Dirofilaria immitis* adult worms. *Parasites Vectors,* 2019; 12(1), 315.





O-8. NONBACTERIAL THROMBOTIC ENDOCARDITIS OF THE TRICUSPID VALVE IN A MALE DOG WITH DIROFILARIASIS CASE REPORT

Radulescu, A. M.¹, [Vulcan, E.T.](#)², Taulescu, M.³

Keywords: Echocardiography, Dirofilariasis, Right heart failure, Tricuspid mass, Endocarditis.

¹University of Agronomic Sciences and Veterinary Medicine of Bucharest, Faculty of Veterinary Medicine, Bucharest, Romania, alice@medicalvet.ro

²University of Agronomic Sciences and Veterinary Medicine of Bucharest, Faculty of Veterinary Medicine, Bucharest, Romania, elena.vulcan@medicalvet.ro

³University of Agronomic Sciences and Veterinary Medicine of Cluj-Napoca, Faculty of Veterinary Medicine, Romania.

This case report describes the echocardiographic and histopathological aspects of endocardial and valvular lesions produced by dead heartworm entangled in the tricuspid valve. An 11-year-old male dog crossbreed was referred to cardiology, presenting signs of right heart failure. Echocardiography revealed a vegetative mass adhering to the tricuspid valve that caused valvular insufficiency. The differential diagnosis for such mass was infective endocarditis, vegetative lesions, thrombus, or neoplasia. The antigenic test confirmed the infestation with the nematode *Dirofilaria immitis*. The definitive diagnosis was confirmed postmortem histopathologically as chronic thrombotic endocarditis with mineralized fragments of parasites trapped in the tricuspid valvular apparatus. Although the phenomenon of endocarditis secondary to worm coiling the tricuspid valve is cited in the literature, to the best of the author's knowledge, echocardiography concomitant with histopathological descriptions of these lesions is rarely reported.





O-9. RIGHT PULMONARY ARTERY DISTENSIBILITY INDEX IN HW INFECTED DOGS: ARE THE DIFFERENT METHODS LEADING TO SAME RESULTS?

Basile, A.¹; Napoli, E.²; Brianti, E.²; Otranto, D.³; Venco, L.⁴

¹ Centro Nefrologico Veterinario/Catania, Italy, angelofrancescobasile@gmail.com

² Department of Veterinary Sciences, University of Messina, Messina, Italy

³ Department of Veterinary Medicine, University of Bari, Valenzano, Italy

⁴ Ospedale Veterinario Città di Pavia, Pavia, Italy

Keywords: dog, *Dirofilaria Immitis*, echocardiography, pulmonary hypertension

Canine Heartworm disease is mainly a pulmonary vasculopathy. Reducing of Pulmonary Arterial Distensibility (PAD) is an early index of vasculopathy even before other evidences of pulmonary hypertension. Echocardiographic evaluation of the right pulmonary artery distensibility index (RPADi) was described as a valuable method for evaluation of PAD both in human beings and in dogs. It is calculated as the percentage change in diameter of the right pulmonary artery (RPA) between systole and diastole. There are two main different published methods for RPADi calculation: Venco method, from the right parasternal long axis view (RPLA) and measuring from leading edge-to-leading edge (lele), using M-mode echocardiography and Visser method, from the right short axis view (RPSA), measuring from trailing edge-to-leading edge (tele), using B-mode echocardiography. Moreover, hybrid methods have also been used. It is, therefore, difficult for a clinician choose which method is better to apply and how to compare its results with the references values reported. The aim of this study was to compare the RPADi obtained by five different techniques. The study design was a retrospective, single center, observational study. Forty-seven client-owned dogs were included, both healthy and *Dirofilaris immitis* infected, with different clinical pictures. Five methods: Venco classic (RPLA, lele), Venco modified (RPLA, tele), Visser classic (B-mode, RPSA, tele), Visser modified 1 (M-mode, tele), and Visser modified 2 (M-mode, lele) have been used. Measurements were done off-line as an average of 3 consecutive cardiac cycles by a single investigator blinded to the dogs' diagnosis. In all methods, the systolic dimension of the pulmonary artery was measured at the maximum diameter (usually at the T wave) and diastolic diameter at its smallest dimension (at the Q wave). A Bland-Altman test (BA) were used to assess agreement among the methods, two by two. Intra-observer measurement variability was quantified by average coefficient of variation (CV) over 3 consecutive cycles. RPAD index was satisfactorily obtained by all methods in all dogs. BA showed a good statistical agreement among the methods, compared two-by-two (bias between 0,0867 and 3,89 %, 95% limits of agreement between -19,2 and 22,76 %). Intra-observer measurement variability was clinically acceptable both for systolic dimension and diastolic one (CV<6 %). The study showed a good agreement between short axis and long axis, both with M-mode and B-mode echocardiography in the evaluation of RPAi. All methods evaluated could be used interchangeably from a statistical point of view, however for a better harmonization and comparison of the results, the scientific community must choose among the different methods and establish reference intervals on the basis of different causes of pulmonary hypertension.





O-10. EVALUATION OF THORACIC COMPUTED TOMOGRAPHY FINDINGS IN DOGS NATURALLY INFECTED BY *DIROFILARIA IMMITIS*

Matos, J.I.¹, Falcón-Cordón, Y.¹, García-Rodríguez, S.N.¹, Costa-Rodríguez, N.¹, Montoya-Alonso, J.A.¹, Carretón, E.¹

¹Internal Medicine, Faculty of Veterinary Medicine, Research Institute of Biomedical and Health Sciences (IUIBS), University of Las Palmas de Gran Canaria, Las Palmas de Gran Canaria, Spain, Jorge.matos@ulpgc.es

Keywords: Heartworm, *Dirofilaria immitis*, Computed Tomography, Pulmonary hypertension, animal diseases

The development of thoracic lesions such as pulmonary thromboembolism, eosinophilic pneumonia, lymphadenomegaly, pulmonary hypertension (PH), and bronchiectasis are common disorders in canine heartworm. However, there have been few reports of computed tomography (CT) imaging findings in heartworm disease. The objective of this study was to show the main thoracic CT findings in a group of dogs parasitized by *D. immitis*.

In this study were evaluated 36 naturally-infected dogs and 30 healthy dogs on the island of Gran Canaria, between September 2019 and July 2022. The presence of PH was determined echocardiographically through the estimation of the right pulmonary artery distensibility index (RPADi<29.5%). Secondly, thoracic CT images with contrast were acquired with a helical CT scanner. Lung and soft tissue reconstructions and adjustments to the width and level of the imaging window were reviewed. Analysis of DICOM CT images was performed on a dedicated image viewing station using commercially available viewing and analysis software.

The measures evaluated by CT were the ratio between the pulmonary trunk and the ascending (PT:AAo) and descending (PT:DAo) Aorta, the ratio between the pulmonary vein and the pulmonary artery (PV:PA), the ratio between the right and left ventricles (RV:RL) and the bronchoarterial ratio (BA), following previously published protocols. In addition, normalized measurements of the diameter of the pulmonary trunk (PTn), right ventricle (RVn), and lobar pulmonary arteries (PAN) were displayed. Finally, the presence of pulmonary alterations such as bronchointerstitial lung pattern, nodules/thickening, alveolar infiltration, bronchiectasis, consolidation, pleural effusion, pneumothorax, peribronchial cuffing, atelectasis and lymphadenopathy was recorded if present.

The RPDi determined the presence of PH in 63,9% of the parasitized animals. The presence of heartworm and PH showed significant results (increased values in PT:AAO, PTDAO, RV:RL, PTn, PAN and RVn, and lower values in PV:PA and BA) compared to healthy animals or infected dogs without PH. 59,1% of the infected animals presented pulmonary lesions, with peribronchial cuffing (66,7%) and bronchointerstitial lung pattern (61,1%) being the most notable findings. Significant results were reported between the presence of PH and other thoracic injuries ($P<0,1$).

In general, the results showed a high presence of cardiorespiratory lesions in dogs with heartworm disease. Chronic and reinfection processes generate PH and multiple thoracic lesions in most of the animals studied. CT can be a useful tool to assess thoracic alterations in patients with heartworm disease. New studies are indicated with a larger sample size, being able to standardize protocols and obtain reliable reference values.

The presented study was supported by own funds from the Veterinary Medicine Service FULP/ULPGC (SD-240/030/0026).





O-11. THE AG POSITIVE AND KNOTT NEGATIVE DOG: SHOULD I TREAT OR SHOULD I NOT?

Venco, L.¹

¹ Ospedale veterinario Città di Pavia, Pavia Italy, luigivenco@libero.it

Keywords: Antigen test, Knott Test, False positive, Predictive value

Heartworm antigen testing is considered sensitive and specific. Currently available tests are reported as detecting a glycoprotein found predominantly in the reproductive tract of the female worm and can reach specificity close to 100%. Main concerns regard sensitivity in the case of light infections, the presence of immature females or cases of all-male infections. Research and development have been aimed at increasing sensitivity. In the last decades, heat treatment of serum (103 °C for 10 min) prior to antigen testing has been shown to result in an increase in positive antigen test results, presumably due to disruption of natural antigen-antibody complexes. Cross-reactions in dogs with both natural and experimental infections with *Angiostrongylus vasorum*, *D.repens* and *Spirocerca lupi* have been reported, but cross-reactions with other helminths have not been extensively studied although ex vivo studies have shown the possibility of cross-reaction with other nematodes and even tapeworms and the heat treatment has shown to increase sensitivity but increasing cross reactivity too.

Both ESDA and AHS GLs suggest performing Antigen Test and Knott Test at the same time, both to increase diagnostic sensitivity but also specificity. In case of a Positive antigen test and a Negative Knott test it could be both a True Positive and a False Positive. In these cases in the dog, instead of resorting to heat treatment it is advisable to run to other investigations that could support the True Positivity. Echocardiography to visualize adults *D. immitis*, chest radiographs to see if there are alterations compatible with HW disease, but also anamnestic data (the dog was doing chemoprophylaxis, the dog lives in an endemic area) which in the ensemble or individually can vary the Positive Predictive Value of the Antigen test. If no other element confirms (echocardiography) or supports (anamnesis, chest x-rays) a diagnosis of infection, the main possibilities are those of a False Positive or True Positive with low worm burden and no pulmonary damages.

An adulticidal treatment with Melarsomina in these cases is therefore certainly not urgent, it could be useless and at the same time deadly infections such as those from *A. vasorum* or *S. lupi* could be neglected. The most rational choice is therefore to undertake a treatment with monthly moxidectin at a dosage of 2.5 mg / kg spot on (active both on *A.vasorum* and *S.lupi* and on other parasites that could induce cross-reaction such as *D. repens* or *Acanthocheilonema sp*) and repeat the antigen test after 7 months.

References

1. Venco L, Manzocchi S, Genchi M, Kramer LH. Heat treatment and false-positive heartworm antigen testing in ex vivo parasites and dogs naturally infected by *Dirofilaria repens* and *Angiostrongylus vasorum*. *Parasit Vectors*. 2017 Nov 9;10(Suppl 2):476.
2. Szatmári V, van Leeuwen MW, Piek CJ, Venco L. False positive antigen test for *Dirofilaria immitis* after heat treatment of the blood sample in a microfilaremic dog infected with *Acanthocheilonema dracunculoides*. *Parasit Vectors*. 2020 Oct 1;13(1):501.





O-12. MEASUREMENT OF CORTISOL IN DOGS INFECTED BY *DIROFILARIA IMMITIS*

Costa-Rodríguez N¹, Matos JI¹, Falcón-Cordón Y¹, Morchón, R.^{1,2}, García-Rodríguez SN¹, Montoya-Alonso JA¹, Carretón E¹.

¹Internal Medicine, Faculty of Veterinary Medicine, Research Institute of Biomedical and Health Sciences (IUIBS), University of Las Palmas de Gran Canaria, Las Palmas de Gran Canaria, Spain, noelia.costa@ulpgc.es

²Zoonotic diseases and One Health group, Laboratory of Parasitology, Faculty of Pharmacy, University of Salamanca, 37007, Salamanca, Spain.

Cortisol, a steroid produced in the adrenal cortex, is a key hormone used as a measure of stress. Some studies demonstrate that prolonged stress, is associated with reduced survival, fecundity and immunity. Moreover, high cortisol levels have been associated with infectious diseases, and it has been demonstrated its utility as a biomarker of chronic stress in cardiovascular disease in humans. Furthermore, previous studies relate the presence of parasites and cortisol levels in several species.

The objectives were evaluating the potentially stressful effects of *Dirofilaria immitis* infection in dogs, comparing the results of cortisol levels with reference values and with other clinical parameters (parasite burden, presence/absence of pulmonary hypertension (PH), microfilarieic status) and evaluate the evolution of serum cortisol levels throughout adulticide treatment in dogs with heartworm.

The serum of 92 heartworm-infected dogs undergoing adulticide therapy was analyzed on days 0, 30, 60 and 90. The parasite load was echocardiographically assessed on day 0 and dogs were further classified based on low/high burden. The presence/absence of pulmonary hypertension was also assessed ultrasonographically by means of Right Pulmonary Artery Distensibility Index. Dogs were classified into two groups according to presence or absence of PH. The presence/absence of microfilariae was determined by using the modified Knott test. Serum cortisol was measured by using VCHECK V200 Veterinary Immunoassay Analyzer (Bionote, Minnesota, USA). Reference ranges for healthy dogs were established as 5±4,5 ng/ml. On day 0, the mean level of cortisol in heartworm infected dogs was 32,16±23,76 ng/ml. The parasite load was high in 30.4% (n=28) and low in 69.6% (n=64). The values of cortisol obtained for microfilarieic (32,39 ± 19,71 ng/ml) and amicrofilarieic (32,91 ± 28,40 ng/ml) dogs had no statistically significant differences; Same results were observed in dogs with a high parasite burden (33,64±24,46 ng/ml) versus dogs with a low burden (31,16 ± 24,09 ng/ml). When PH was evaluated, dogs with PH showed higher levels of cortisol (36,25±19,04 ng/ml) compared with dogs without PH (28,26±24,10 ng/ml) being a statistically significant difference (p<0.05) During the adulticide treatment, the levels of cortisol varied until reaching the lowest value on day 90 (17.58±1.02 ng/ml). In all time point measurements, significant differences were found when compared to reference values (p<0.05 for all time points). When evaluating the variations in cortisol levels throughout the study, statistically significant differences were found between the cortisol values obtained on day 90 compared to the values obtained at the other time points (p<0.05 for days 0, 30 and 60).

The results demonstrated stress in dogs infected by *D. immitis*, especially in those with presence of PH. Moreover, at the end of the treatment, when the parasites were eliminated, the levels of cortisol decreased, although remained above reference ranges. These results are similar to other studies which evaluated the effect of cortisol in several parasites in dogs. Accordingly, cortisol could be used as a supporting biomarker in the clinical staging of dogs with heartworm disease. This study was supported by the Servicio Medicina Veterinaria FULP/ULPGC SD-240/030/0026.

References

1. Carretón E, Falcón-Cordón Y, Falcón-Cordón S, Morchón R, Matos JI, Montoya-Alonso JA. Variation of the adulticide protocol for the treatment of canine heartworm infection: can it be shorter? *Vet. Parasitol.* 2019; 271, pp. 54-56
2. Carretón E, Morchón R, González-Miguel J, Simón F, Juste MC, Montoya-Alonso JA. Variation of D-dimer values as assessment of pulmonary thromboembolism during adulticide treatment of heartworm disease in dogs. *Vet Parasitol.* 2013 Jul 1;195(1-2):106-11.
3. Morchón R, Carretón E, González-Miguel J, Mellado-Hernández I. Heartworm Disease (*Dirofilaria immitis*) and Their Vectors in Europe – New Distribution Trends. *Frontiers in Physiology.* 2012;3.
4. Venco, L, Genchi, C, Vigevani Colson P, Kramer, L. Relative utility of echocardiography, radiography, serologic testing and microfilariae counts to predict adultworm burden in dogs naturally infected with heartworms. In: Seward, R.L., Knight, D.H. (Eds.), *Recent Advances in Heartworm Disease, Symposium'01.* American Heartworm Society. Batavia, IL. 2003;pp. 111–124
5. Visser D.M, Bruijning M, Wright S.J, Muller-Landau C.H, Jongejans E, Comita S.L, de Kroon H. Functional traits as predictors of vital rates across the life cycle of tropical trees. 2016; <https://doi.org/10.1111/1365-2435.12621>





O-13. CLINICAL AND RADIOLOGICAL FINDINGS IN CATS NATURALLY AFFECTED BY HEARTWORM ASSOCIATED RESPIRATORY DISEASE.

García-Rodríguez, S.N.¹, Matos, J.I.¹, Costa-Rodríguez, N.¹, Falcón-Cordón, Y.¹, Carretón, E.¹, Montoya-Alonso, J.A.¹

¹Internal Medicine, Faculty of Veterinary Medicine, Research Institute of Biomedical and Health Sciences (IUIBS), University of Las Palmas de Gran Canaria, Las Palmas de Gran Canaria, Spain., saranieves.garcia@ulpgc.es

Keywords: Heartworm disease, *Dirofilaria immitis*, Cat, Radiography, Animal disease.

The clinical and radiological findings observed in feline heartworm disease can be very similar to other respiratory pathologies, such as feline asthma or chronic bronchitis. This, added to the difficulty in establishing a clinical diagnosis, means that on many occasions the definitive diagnosis is not reached. Nowadays, only one previous study is known to assess the clinical course and radiological findings of asymptomatic cats naturally infected by *Dirofilaria immitis*. The objective of this study was to assess the symptoms, immunological tests and the presence of radiological findings observed in cats naturally infected by immature larvae of *D. immitis*. Twenty cats diagnosed with Heartworm Associated Respiratory Disease (HARD) through the indirect ELISA technique for the detection of *D. immitis* antibodies (in-house ELISA, Urano Vet®, Barcelona, Spain) were included. These animals were studied between January and July 2022 at the Veterinary Clinical Hospital of University of Las Palmas de Gran Canaria (Gran Canaria, Spain). Data on age, breed, sex, habitat and presence of symptoms were collected. Furthermore, the rapid test for the detection of antigens against leukemia (FeLV) and feline immunodeficiency antibodies (FIV) was carried out (Urano Vet®, Barcelona, Spain). Subsequently, thoracic radiographs with two projections (latero-lateral, and ventro-dorsal) were carried out in all the cats studied. The cardiac silhouette was assessed through Vertebral Heart Score (cut off >7.8). Moreover, the pulmonary pattern, pulmonary opacity, and the distribution of pulmonary lesions were evaluated. The most common clinical signs were those of respiratory origin, with 16 cats (80%) presenting for cough and/or dyspnea. Meanwhile, 2/20 (10%) had gastrointestinal symptoms (diarrhea). Finally, 2/20 (10%) had no symptoms. In immunological tests, 10% of cats were positive for FeLV and 5% of cats were positive for FIV. Through VHS it was observed that 15% cats showed an increase in the size of the cardiac silhouette. Lung appearance was variable in all animals studied. Abnormalities of the pulmonary arteries were observed in 20%. The most common pulmonary findings were broncho-interstitial (80%), interstitial (15%), and alveolar (5%). 10% cats showed no abnormalities in the lung parenchyma. No cat showed pleural effusion. Pulmonary lesions were mainly observed with a diffuse and bilateral distribution pattern, affecting the caudal lobes with greater severity. The results of this study show that the combination of clinical findings and radiological study is quite useful to suspect HARD in endemic areas, thus emphasizing the importance of including this disease in the differential diagnosis. Despite the absence of a significant correlation in the presence of FeLV-FIV coinfections with feline dirofilariosis, it is proposed to continue assessing it with a greater number of samples, taking into account, above all, cats that live outdoors.

The present study was supported by Merck Sharp and Dohme Animal Health, S.L (CN-240/030/158).

References

1. Venco, L., Genchi, C., Genchi, M., Grandi, G., & Kramer, L. H. Clinical evolution and radiographic findings of feline heartworm infection in asymptomatic cats. *Veterinary Parasitology* 2008; 158:232-237.



O-14. ASSESSMENT OF TTE (TRANSTHORACIC ECHOCARDIOGRAPHY) GUIDANCE DURING CAVAL SYNDROME SURGERY

Leca, F.^{1,2}, Geanta, S.A.^{1,2}, Bolintineanu M.C.¹, Minca N.A.²

¹"Doctor's Vet Univers" Clinic, Bucharest, Romania, cabinetcardiologieveterinara@gmail.com

²Faculty of Veterinary Medicine Bucharest, Romania

Keywords: Heartworm, Caval Syndrome, Mechanical removal, Fluoroscopy.

Caval Syndrome management is ensured by the emergency removal of the filariae and by treating the systemic complications and hemolytic syndrome. The filariae embolectomy can be performed under no imaging guidance (not recommended) or by fluoroscopy, transthoracic echocardiography (TTE) and transesophageal echocardiography (TEE) guidance. In this study the efficacy and limitations associated with TTE imaging guidance during Caval Syndrome surgery were assessed. This study included a number of 45 cases diagnosed with a mass of intracardiac worms, over a period of 9 years (2013-2022). Out of the 45 cases, 36 were classified with Caval Syndrome (intravascular hemolysis-pallor, pigmenturia). The surgical procedure was performed under TTE guidance (31 cases) and under hybrid TTE and fluoroscopy guidance (5 cases) in the Interventional Cardiology Laboratory of our clinic. Total intravenous anesthesia was performed using chemical restraint protocols (Benzodiazepine and Butorphanol) and dissociative agent (Ketamine administered bolus IV, continued as CRI for maintenance and pain control). The surgical technique consisted of right external jugular vein venotomy (surgical "cut-down"), representing the venous access port for the introduction of embolectomy instruments (Retrieval basket, Tripod grasping forceps, Clear-It flexible alligator forceps, Rigid alligator forceps or single/multiple wire semiflexible loop). Filariae from the right atrium were extracted and the jugular vein was ligated or preserved. In cases where surgery was performed only under TTE guidance, the main disadvantages were represented by difficult passage of the embolectomy tool from the level of the external jugular vein to the right atrium, as it could pass through the following veins: azygos (Fig. 1), axillary or inferior vena cava (Fig. 2). The rapidity, the outcome are highly dependent on the ultrasonographer's and surgeon's skills. The advantages of using TTE guidance were: good visualization of the parasites at the level of the heart before and after their extraction, the precise "arming" of the embolectomy device (Fig. 3), extracting the filariae without causing any damage to the tricuspid valve and without dislocating the filariae caught in the valvular or subvalvular apparatus. Dislodging the preexistent ulcero-vegetative or thrombotic endocarditis was also avoided. Using only the TTE has the main disadvantages of poor guidance and visualization of the embolectomy tools from the access port to the right atrium/right ventricle, associated with increased surgical time, which is detrimental to the hemodynamically unstable patient. Using a hybrid TTE-Fluoroscopy imaging guidance technique enhances the advantages of each technique, as follows: decreasing of both the exposure of the medical team to radiation (5 minutes) and the operating time (a duration of approximately 20 minutes using the hybrid technique, compared to 45 -120 minutes using only TTE) were achieved, good guidance and a good visualization of both the device and the parasites were obtained throughout the procedure.

References

1. Ames, M. and Atkins, C., 2020. Treatment of dogs with severe heartworm disease. *Veterinary Parasitology*, 283, p.109131.
2. Pariaut, R., Jung, S., Vila, J. and Newhard, D., 2020. Resolution of caval syndrome during initial hemodynamic stabilization in dogs with heartworm disease. *Journal of Veterinary Emergency and Critical Care*, 30(3), pp.295-301.
3. Romano, A., Saunders, A., Gordon, S. and Wesselowski, S., 2020. Intracardiac heartworms in dogs: Clinical and echocardiographic characteristics in 72 cases (2010-2019). *Journal of Veterinary Internal Medicine*, 35(1), pp.88-97.

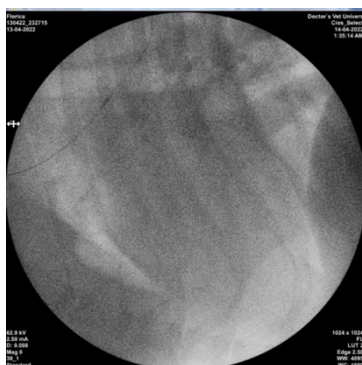


Fig. 1

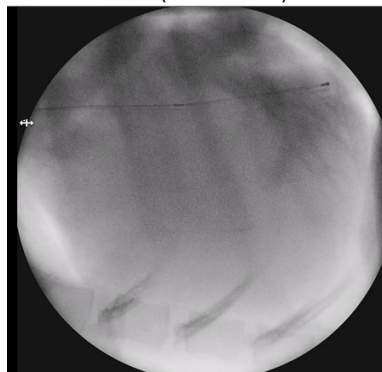


Fig. 2

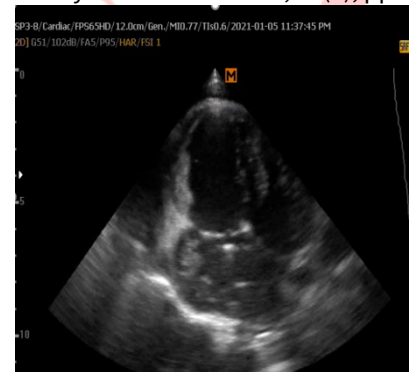


Fig. 3



O-15. LIVER ASSESSMENT OF DOGS NATURALLY INFECTED BY *DIROFILARIA IMMITIS*

Matos, M.D.¹; Soares, D.V.²; Bendas, A.J.³; Alberigi, B.³

¹Programa de Pós-Graduação em Medicina Veterinária, Instituto de Veterinária, Universidade Federal Rural do Rio de Janeiro (Federal Rural University of Rio de Janeiro), Seropédica, Brazil,

²Diagnostic Imaging Service – Via Care clínica veterinária, Rio de Janeiro, Brazil

³Departamento de Medicina e Cirurgia Veterinária, Instituto de Veterinária, Universidade Federal Rural do Rio de Janeiro (Federal Rural University of Rio de Janeiro), Seropédica, Brazil, bruno.alberigi@gmail.com

Keywords: liver, heartworm, ultrasound

Canine cardiopulmonary abnormalities in *D.immitis* infected dogs are well known, however little attention is addressed to other organs that can be affected. With the inflammatory stimulus caused by the worm in the pulmonary vessels and the increased pulmonary pressure, right congestive heart failure occurs and consequently, hepatic congestion happens. The aim of the present work is to report findings of liver assessment in the ultrasound examination (B-Mode and Dopplervelocimetric evaluation of the hepatic vein) and laboratory tests in six *D. immitis* naturally infected American Staffordshire terrier dogs.

The dogs age range was 8 ± 1.6 years (three males and three females). The owner reported that although some dogs coughed, no dog had any other clinical symptoms. All dogs had normal mucous membranes, with a mean body weight of 17.5 ± 4 kg with a normal body condition score. The ultrasound evaluation showed that five dogs had hepatomegaly and one dog had a normal-sized liver. Two dogs presented normal liver echogenicity, two a hypoechoic liver and two a hyperechoic liver. Five dogs presented heterogeneous hepatic parenchyma echotexture and only one presented homogeneous echotexture. The gallbladder was normal in one dog and all the others had a slight amount of biliary sludge. When evaluating the hepatic vascular architecture, enlargement of the hepatic vessels was observed in only one dog. No other abnormalities were observed in the B-Mode. On the Doppler velocimetry evaluation of the hepatic vein, all dogs presented a triphasic wave pattern, with visualization of the A, S and D waves. The A wave velocity had a mean of 18.6 ± 5.5 cm/s, S wave 40.2 ± 17.0 cm/s, D wave 28.8 ± 15.6 cm/s and the S/D ratio was 1.5 ± 0.3 . All CBC's and albumin levels were within the normal range. Three dogs presented increased alkaline phosphatase. GGT was normal for the 2 dogs in which it was dosed.

It is noteworthy that all dogs presented hepatic abnormalities, without any clinical signs of systemic illness that justify the alterations, suggesting that HTW could be the cause of it. However, the cardiac evaluation was not performed, and it was impossible to make any direct correlation of hemodynamic with the observed abnormalities. According to a study conducted in dogs with right heart disease, a reduction in the value of the S/D ratio was also observed. The velocities of A, S and D waves were higher than the animals with right cardiac disease and the control group from different studies. However the lack of a control group for these dogs precludes any conclusion. Therefore, further studies on the influence of HTW on the liver of naturally infected dogs are needed, although these results suggest that HTW dogs must be thoroughly examined.

References

1. Nelson CT, McCall JW, Jones S, Moorhead A. Current canine guidelines for the prevention, diagnosis, and management of heartworm (*Dirofilaria immitis*) infection in dogs 2020. https://d3ft8sckhnm2.cloudfront.net/images/pdf/2020_AHS_Canine_Guidelines.pdf?1580934824. Accessed 23 July 2022.
2. Kim J, Kim S, Eom K. Pulsed-wave Doppler ultrasonographic evaluation of hepatic vein in dogs with tricuspid regurgitation. J Vet Sci. 2017 Mar 30;18(1):73-79.





O-16. EFFECT OF MOXY-DOXY TREATMENT ON THE LUNGS OF DOGS NATURALLY INFECTED WITH *DIROFILARIA IMMITIS*

Alberigi, B.¹; Knackfuss, F²; Soares, D.V³; Fernandes, J.I.¹; Labarthe, N⁴.

¹Departamento de Medicina e Cirurgia Veterinária, Instituto de Veterinária, Universidade Federal Rural do Rio de Janeiro (Federal Rural University of Rio de Janeiro), Seropédica, Brazil, bruno.alberigi@gmail.com

²Curso de Medicina Veterinária, Universidade do Grande Rio, Duque de Caxias, Brazil

³Diagnostic Imaging Service - Instituto de Especialidades em Medicina Veterinária, Rio de Janeiro, Brazil

⁴Programa de Pós-graduação em Ética, Bioética e Saúde Coletiva, Fundação Oswaldo Cruz, Rio de Janeiro, Brazil

Keywords: Lungs, heartworm, x-ray

Dirofilaria immitis infected dogs present inflammation of their lungs that may generate hemodynamic repercussions and congestive heart failure. Regardless of hemodynamic status, the inflammation is responsible for clinical manifestations such as cough, dyspnoea and exercise intolerance. The objective of treating the infection is to eliminate all life stages of the parasite in the dog and to improve its wellbeing. The conventional treatment is the use of melarsomine associated with doxycycline and macrocyclic lactones. However, in countries where melarsomine is not available, treatment with association of moxidectin and doxycycline (MOXY-DOXY) is frequently used. This treatment is based on the slow death of the parasites, which could allow the worsening of the lungs conditions once parasites will remain for a longer time in the pulmonary vessels. The aim of this work was to evaluate if the treatment with MOXY-DOXY in naturally infected by dogs would allow the worsening of the lungs.

Nineteen naturally infected dogs, aged between 1 and 8 years old, were evaluated (9 males and 11 females). Each dog received a treatment consisting of a single administration of extended-release injectable moxidectin suspension (ProHeart® SR-12) 0.5 mg moxidectin/kg and doxycycline administered orally at 10 mg/kg bid for 30 days every 6 months. Dogs were considered cleared when they tested negative twice with 6 months interval. The dogs' lungs were evaluated before and after treatment by clinical examination (presence of cough, dyspnea, and the presence of abnormal lung sounds) and by x-ray (caudal pulmonary artery enlargement, main pulmonary artery enlargement, bronchial + interstitial pattern and micronodular pattern). The mean time of treatment was 445±110 days. Before treatment all dogs presented lung abnormalities. Seven dogs (36.8%) presented coughing at enrollment and after treatment only one (5.3%) was still coughing although, according to the owner, less than before. Three dogs (15.8%) initially presented dyspnea and when cleared all were eupneic. Sixteen dogs (84.2%) presented abnormalities in lung sounds, and when cleared, only two (10.5%) presented increased expiratory sounds. In the radiographic evaluation eight dogs (42.1%) presented enlargement of the caudal pulmonary artery and pulmonary main trunk before treatment and when cleared two dogs (10.5%) still presented increased caliber of the caudal pulmonary artery while three (15.8%) had pulmonary trunk enlargement. All dogs presented bronchial and interstitial patterns when enrolled and when cleared none showed worsening. The micronodular pattern was observed in six dogs (31.6%) and when cleared, seven (36.8) showed the micronodular pattern. Therefore, these results show that during treatment with MOXY-DOXY lungs conditions didn't worsen and that clinical and radiographic parameters improved.

References

1. Nelson CT, McCall JW, Jones S, Moorhead A. Current canine guidelines for the prevention, diagnosis, and management of heartworm (*Dirofilaria immitis*) infection in dogs 2020. https://d3ft8sckhnm2.cloudfront.net/images/pdf/2020_AHS_Canine_Guidelines.pdf?1580934824. Accessed 23 July 2022.
2. Simón F, Siles-Lucas M, Morchon R, Gonzalez-Migue J, Mellado I, Carreton E, Montoya-Alonso JA. Human and animal dirofilariasis: the emergence of a zoonotic mosaic. Clin Microbiol Rev. 2012 Jul;25(3):507–44.
3. Venco L, McCall JW, Guerrero J, Genchi C. Efficacy of long-term monthly administration of ivermectin on the progress of naturally acquired heartworm infections in dogs. Vet Parasitol. 2004 Oct;124(3-4):259–68.





O-17. ANGIOSTRONGYLOSIS IN THE UNITED KINGDOM. CLINICAL CHARACTERISTICS OF AN INCREASINGLY FREQUENT PATHOLOGY: DESCRIPTION OF 5 CASES

Falcon-Cordón, Y.¹, Carretón Gómez, E.¹, Morchón, R.^{1,2}, Falcon-Cordón, S.¹, Costa Rodríguez, N.¹, Matos Rivero, J.I.¹, García Rodríguez, S.¹, Montoya-Alonso, J.A.¹

¹Faculty of Veterinary Medicine, Research Institute of Biomedical and Health Sciences (IUIBS), University of Las Palmas de Gran Canaria, Arucas, 35413, Las Palmas, Spain, yaiza.falcon@ulpgc.es

²Zoonotic diseases and One Health group, Laboratory of Parasitology, Faculty of Pharmacy, University of Salamanca, 37007, Salamanca, Spain.

Keywords: canine angiostrongylosis, clinical aspects, case description, lungworm.

Angiostrongylus vasorum infection has been considered endemic in different regions of the United Kingdom and it is wide spread in Europe. It is caused by a metastrongyloid nematode and mainly affects wild carnivores and dogs and they are affected usually due to the ingestion of gastropod molluscs (slugs or snails). The objective of this study was to describe the clinical presentation of the disease, diagnosis and treatment. To this aim, 5 dogs between 8 month and 10 years old, 3 males and 2 females, were presented in consultation with a history of tachypnoea, dyspnoea, coughing, exercise intolerance and epistaxis. None of them was receiving preventive treatment against lungworm for more than 2 years. Physical exam showed not evident signs of illness in 1 of them (asymptomatic); the rest of the patients showed sinus tachycardia, crackles and broncoalveolar noises in auscultation. One of the dogs presented right heart murmur without presence of jugular pulses or hepatojugular reflex. After reviewing history details and physical exam data, blood samples were collected to perform an in-house serological assay for the detection of antigens (Angio Detect, IDEXX Laboratories)TM and three different days of faeces samples in order to do a coproscopic examination. All the dogs tested positive to serological assay and the diagnosis was confirmed by the faeces Baermann test were all dogs were positive. After diagnosis, further investigation as blood test, including haematology, chemistry and coagulation test, thorax xrays and echocardiography were performed to assess treatment and prognosis. Haematology abnormalities were found in 2 dogs including mild anaemia, eosinophilia and trombocytopenia. Biochemical results were normal and coagulation parameters were altered in 1 dog. Radiographic findings included alveolar infiltrate and bronchial thickening and increased sternal contact, indicating right heart enlargement, truncated pulmonary arteries and increased Vertebral Heart Score. Echocardiography exams demonstrated dilation of the right ventricle and atrium in 1 dog, dilated vena cava with clot formation in 1 dog and moderated tricuspid valve regurgitation in 2 of the dogs studied. Treatment was started with milbemycin oxime in combination with praziquantel tablets once weekly for four weeks against *A. vasorum*, and supportive treatment including pimobendan and sildenafil for pulmonary hypertension. Anti-inflammatory steroids doses was used to moderate respiratory signs. In conclusion, to improve the understanding and diagnosis of angiostrongylosis, new endemic areas should be defined in the United Kingdom as diagnosis of Canine Angiostrongylosis could be challenging for veterinary surgeons due to variability of clinical signs. Mechanisms leading coagulopathies need to be identified, however supportive treatment is necessary to reduce chronic cardiovascular disease.

References

1. Carretón, E.; Morchón, R.; Falcón-Cordón, Y.; Matos, J.; Costa-Rodríguez, N.; Montoya-Alonso, J.A. First epidemiological survey of *Angiostrongylus vasorum* in domestic dogs from Spain. *Parasit. Vectors* 2020, 13, 306
2. Borgeat K, Sudunagunta S, Kaye B, Stern J, Luis Fuentes V, Connolly D J. Retrospective evaluation of moderate to severe pulmonary hypertension in dogs naturally infected with *Angiostrongylus vasorum*. *J Small Anim Pract* 56:196–202, 2015
3. Elsheikha, H.M.; Holmes, S.A.; Wright, I.; Morgan, E.R.; Lacher, D.W. Recent advances in the epidemiology, clinical and diagnostic features, and control of canine cardio-pulmonary angiostrongylosis. *Vet. Res.* 2014, 45, 92.





O-18. ATYPICAL INTRAOCULAR MIGRATION OF *ANGIOSTRONGYLUS VASORUM*

Filipescu, I.E.¹, Vergara, M.¹, Manzocchi, S.², Neroni, M.³, Morelli, S.⁴

¹Freelance Veterinary Doctor, Italy, filipescu.iuliaelena@yahoo.com

²IDEXX Laboratories, Novara Day Lab, Novara, Italy.

³Lungonera Veterinary Clinic, Narni Street, Terni, Italy.

⁴Faculty of Veterinary Medicine Teramo, Department of Parasitology, Teramo, Italy.

Keywords: *Angiostrongylus vasorum*, intraocular angiostrongylosis, lungworm.

This report describes the case of two intraocular *A. vasorum* specimens in an 18-months old dog living in the countryside of Terni, Central Italy.

The patient was referred for an ophthalmological examination due to the presence of two motile parasites in the anterior chamber of one eye. The medical history showed that he had several episodes of recurrent cough in the past. Physical and imaging (thoracic X-ray and ultrasound) examinations were carried out, along with a complete hematobiochemical analysis and modified Knott test. The intraocular parasites were surgically removed and preserved in 70% ethanol for morphological and biomolecular identification. Serum and aqueous humor were tested for antigens of *Dirofilaria immitis* (SNAP 4DX Plus, IDEXX, Westbrook, US) and *A. vasorum* (AngioDetect, IDEXX, Westbrook, US). A stool sample has been examined using the Baermann's method.

The intraocular parasites were morphologically consistent with metastrongylid and identified by PCR as *A. vasorum*. Both serum and aqueous humor yielded positive for AngioDetect test, and larvae of *A. vasorum* were retrieved at the Baermann's test. All tests for *D. immitis* were negative. Thoracic X-ray and ultrasound showed findings compatible with angiostrongylosis, i.e. areas of subpleural lung consolidation.

This clinical case demonstrates the importance of including *A. vasorum* in the differential diagnosis of canine ocular diseases. Furthermore, an update of the current epidemiological distribution of *A. vasorum* in Italy would be of great help for local vets towards appropriate diagnostic, prevention and treatment approaches for angiostrongylosis.





O-19. ANTIGENAL EVALUATION OF DIROFILARIASIS AND ANGIOSTRONGYLOSIS IN DOGS FROM NORTHERN AND CENTRAL PORTUGAL

Leal-Sousa, B.¹, Esteves-Guimarães, J.², Lobo, L.³, Oliveira P.⁴, Silvestre-Ferreira A.C.⁵, Matos J.I.⁶, Carretón, E.⁶, Montoya-Alonso, J.A.⁶, Fontes-Sousa, A.P.⁷

¹Cat Clinic, Porto, Portugal

²Breed, Santa Maria da Feira, Portugal

³Veterinary Hospital of Porto, Porto, Portugal; Faculdade de Medicina Veterinária, Universidade Lusófona de Humanidades e Tecnologias, Lisboa, Portugal; Center for the Study of Animal Sciences, CECA-ICETA, University of Porto, Porto, Portugal

⁴EPIUnit/Abel Salazar Biomedical Sciences Institute, ISPUP, University of Porto, Porto, Portugal

⁵Animal and Veterinary Research Centre (CECAV), University of Trás-os-Montes and Alto Douro, Quinta de Prados, 5000-801, Vila Real, Portugal; Department of Veterinary Sciences, University of Trás-os-Montes and Alto Douro, Quinta de Prados, 5000-801, Vila Real, Portugal; Associate Laboratory for Animal and Veterinary Science (AL4Animals), Portugal

⁶Research Institute of Biomedical and Health Sciences (IUIBS), University of Las Palmas de Gran Canaria, 35001 Las Palmas de Gran Canaria, Spain

⁷Center for Pharmacological Research and Drug Innovation (MedInUP), Imuno-Physiology and Pharmacology Department, Abel Salazar Biomedical Sciences Institute, University of Porto (ICBAS-UP), Porto, Portugal, apsousa@icbas.up.pt

Keywords: Dirofilariasis, Angiostrongylosis, Dogs, Portugal, Prevalence

Canine dirofilariasis is a relevant vector-borne disease with established importance due to its zoonotic potential and emergency worldwide. Canine angiostrongylosis is another emerging disease with fatal outcomes in dogs and increasingly reports throughout Europe. Several factors are involved in the spreading of these diseases, such as climatic and ecological changes and its impact on the distribution and density of vectors (or intermediate hosts), increased pet traveling, expansion and movement of wild reservoirs and stray dogs' populations and lack of preventive measures in non-endemic areas. The aim of the present study was to assess the prevalence of infection with *Dirofilaria immitis* and *Angiostrongylus vasorum* in the canine population of northern and central Portugal.

Serum samples were collected from 200 domestic dogs in 11 veterinary clinics and hospitals from 7 districts (Aveiro, Braga, Bragança, Porto, Viana do Castelo, Vila Real, Viseu). Two commercial rapid in-clinic serological tests were used for qualitative detection of *D. immitis* and *A. vasorum* antigens. A complete clinical record was kept for each dog through a model questionnaire. The χ^2 and Fisher's exact tests were used to evaluate the association between potential risk factors and positivity to each pathogen.

The overall prevalence was 3% and 1% for *D. immitis* and *A. vasorum*, respectively. Districts like Aveiro (5.3%) and Viana do Castelo (9.5%), revealed higher *D. immitis* prevalence. Positive cases for *A. vasorum* were only detected in Aveiro and Viana do Castelo. Regarding positive *D. immitis* dogs, around 67% were males and 33% females, 50% were 1 to 4 years old, 33% were 5 to 9 years old and 17% were 10 to 14 years old. Half of the positive cases lived mixed indoors and outdoors, about 33% lived outdoors and 17% lived indoors. No positive cases were detected in long haired dogs, being 83% short and 17% medium haired. About 67% cases had regular treatment with ectoparasiticides and 50% used to travel to places far from the district of origin. About 83% had related clinical signs. Concerning positive *A. vasorum* cases, all were medium haired, male dogs and had regular treatment with ectoparasiticides; 50% were 5 to 9 years old and 50% were 10 to 14 years old. Half of them lived mixed indoors and outdoors and the other half lived outdoors. Half of them used to travel to places far from the district of origin and 50% had clinical signs.

Dogs living in northern and central regions of Portugal are at risk of acquiring infection with *D. immitis* and *A. vasorum*. Its detection together with the general lack of owners' compliance regarding prophylactic measures, justify the need of adapting protocols in those local areas.





O-20. A NEW COMPLEX DIAGNOSTIC APPROACH FOR DETECTION OF *DIROFILARIA REPENS* INFECTIONS

Pękacz, M.^{1,2}, Basałaj, K.¹, Bąska, P.³, Miterpáková, M.⁴, Stopka, D.⁵, Klockiewicz, M.², Wiśniewski, M.², Zawistowska-Deniziak, A.¹

¹ Witold Stefański Institute of Parasitology, Polish Academy of Sciences, Department Of Host Parasites Molecular Interactions, Warsaw, Poland, pekaczmateusz@gmail.com

²Warsaw University of Life Sciences-SGGW, Division Of Parasitology, Department Of Preclinical Sciences, Faculty Of Veterinary Medicine, Warsaw, Poland

³Warsaw University of Life Sciences, Division Of Pharmacology And Toxicology, Department Of Preclinical Sciences, Faculty Of Veterinary Medicine, Warsaw, Poland

⁴Institute of Parasitology, Slovak Academy of Sciences, Laboratory Of Veterinary Parasitology, Košice, Slovak Republic

⁵Warsaw University of Life Sciences-SGGW, Division Of Pathology, Department Of Pathology And Veterinary Diagnostics, Faculty Of Veterinary Medicine, Warsaw, Poland

Keywords: dirofilariosis, amicrofilaremic, diagnostic

Subcutaneous dirofilariosis is a vector-borne zoonosis caused by parasitic nematode *Dirofilaria repens*. Currently diagnostic methods are based on the occurrence of microfilariae in the bloodstream, ineffective in case of amicrofilaremic infections. Therefore the aim of our study was to develop a new sensitive and specific diagnostic method. Our approach is based on both serological and molecular techniques.

First, we obtained a recombinant form of *D. repens* protein considered as highly L3 stage-specific and estimate its diagnostic potential with almost 700 sera collected from infected and non-infected dogs. As an alternative we used short synthetic peptides selected in our recent research using phage display technology [1]. Collected sera samples were classified as positive (microfilaremic/amicrofilaremic) or negative based on: Knott's test, *Dirofilaria repens* Somatic Antigen (DrSA) ELISA and Real-Time PCR (qPCR). Additionally, we identified 3 specific *D. repens* cell-free DNA fragments circulating in the host bloodstream. The use of species-specific primers and MGB-Eclipse probes enabled the development of a new multiplex qPCR based on genomic and cell-free DNA.

Selected peptides allowed the detection of infected dogs with and without active microfilaremia. Remarkably, results showed a similar pattern to DrSA ELISA and were confirmed by qPCR. Our molecular method enables the detection of fewer than 10 copies of the gene of interest and a fast single-tube differentiation between *D. repens* and *D. immitis* and co-infections of these two species.

Our serological method is a first step to developing a new diagnostic tool that may be used for early diagnosis of dirofilariosis. Application of synthetic peptides instead of native parasite antigens facilitate commercialization of the method and point-of-care testing that could help control the spread of the zoonosis. In addition, the multiplex qPCR may be an alternative for quick confirmation and differentiation of infection.

Financial support for this study was provided by The National Centre for Research and Development, Poland (grant LIDER IX 0106/L-9/2017).

References

1. Pękacz M, Basałaj K, Kalinowska A, Klockiewicz M, Stopka D, Bąska P, Długosz E, Karabowicz J, Młocicki D, Wiśniewski M, Zawistowska-Deniziak A. Selection of new diagnostic markers for *Dirofilaria repens* infections with the use of phage display technology. *Sci Rep.* 2022 Feb 10;12(1):2288. doi: 10.1038/s41598-022-06116-8. PMID: 35145147; PMCID: PMC8831495.





O-21. DIROFILARIA REPENS SOMATIC ANTIGEN REDUCES THE INFLAMMATORY CYTOKINES IN HUMAN DENDRITIC CELLS AND INDUCES TH2 IMMUNE RESPONSE IN NAÏVE CD4 T CELLS

Pękacz M.^{1,2}; Kalinowska A.¹; Basała K.¹; Wesołowska A.¹; Zawistowska-Deniziak A.^{1*}

¹Witold Stefanski Institute of Parasitology, Polish Academy of Sciences, Twarda 51/55, 00-818 Warsaw, Poland, anna.zawistowskad@gmail.com

²Division of Parasitology, Department of Preclinical Sciences, Faculty of Veterinary Medicine, Warsaw University of Life Sciences, Warsaw, Poland

Keywords: *Dirofilaria repens*, immunomodulation, dendritic cells

Dirofilaria repens is a parasitic nematode causing a vector-borne disease called dirofilariasis, an increasingly human zoonosis spreading by mosquitos. *D. repens* infections are a significant problem in veterinary but also human medicine. Worms (helminths) are among the most efficacious organisms in the modulation of their host immune system thanks to various mechanisms developed during many years of host-parasite co-evolution. Macrophages and dendritic cells (DCs), as antigen presenting cells, are interacting with helminth-derived molecules that could influence both their maturation and polarization state. The immune responses induced during *Dirofilaria repens* infections are not fully understood and little is currently known about its impact on DCs and their capacity to prime specific CD4⁺ T cell subsets. In the present study, we therefore investigate the immunomodulatory effects of *Dirofilaria repens* molecules on human dendritic cells.

Using an *in vitro* model of primary monocyte-derived human dendritic cells (moDC), we first characterized the effects of increasing concentrations of *Dirofilaria repens* somatic antigen (*DrSA*) on cytokines secretion in LPS-stimulated moDC. After 48h of stimulation, a potent decrease in IL-6 and TNF- α secretion was evidenced in LPS-stimulated DC treated with *DrSA*. After restimulation with a CD40L-expressing cell line mimicking the interaction with T cells, the inhibition of IL-6 secretion was still present.

We next evaluate the impact of *DrSA* priming in LPS-stimulated DCs on naïve CD4⁺ T cell polarization using a model of DC-allogenic T cell co-culture. After 2 weeks, the cytokines production by T cells was determined by ELISA and a dose-dependent increase in the IL4/IFN γ ratio was observed, indicating that priming DC with *DrSA* induces a Th2 immune response. Altogether, our data suggest that *DrSA* reduce the inflammatory response in human moDCs resulting in a higher capacity to skew naïve T cells towards a Th2 profile. Further studies are required to elucidate the exact underlying mechanism by which *Dirofilaria repens* molecules modulate DC functions and to explore the *in vivo* relevance of these findings in various models of inflammatory diseases.

Financial support for this study was provided by The National Centre for Research and Development, Poland (grant LIDER IX 0106/L-9/2017).





Poster presentations

P-1. HIGH PREVALENCE OF CARDIOPULMONARY PARASITE INFECTION IN RED FOXES (*Vulpes vulpes*) IN NW SPAIN

Barrera JP.¹, Montoya A.¹, Checa R.¹, López-Beceiro AM.², Fidalgo LE.², Foncubierta C.¹, Moraleda P.¹, Estévez-Sánchez E.¹, Miró G.¹.

¹Departamento de Sanidad Animal, Facultad de Veterinaria, Universidad Complutense de Madrid, Avda. Puerta de Hierro s/n, Madrid, España, jbarrera@ucm.es

²Departamento de Anatomía, Producción Animal y Ciencias Clínicas Veterinarias, Facultad de Veterinaria, Universidade de Santiago de Compostela, Lugo, España.

Keywords: *Angiostrongylus vasorum*, *Crenosoma vulpis*, *Eucoleus aerophilus*, Fox, Northwestern Spain

The red fox (*Vulpes vulpes*) is the most successful of mesocarnivores in terms of its expansion. This makes it important to know the infectious diseases that affect this highly adaptable species. Foxes are known for their incursions in search of food, such that peri-urban and even urban areas are hot spots for interactions with humans and other animals. Currently, respiratory infections by nematodes seem to be on the increase, especially those caused by *Angiostrongylus vasorum*. In dogs, this cardiopulmonary parasite can produce severe clinical symptoms.

In the autonomous community of Galicia (NW Spain), red fox populations are controlled through hunting. We took advantage of this and, for 5 consecutive years (2016 to 2020), we examined in the months of January and February, the cardiopulmonary systems of 346 foxes (A Coruña n=81, Lugo n=194, Ourense n=16 and Pontevedra n=54). Cardiopulmonary parasites were detected using dissection and visual inspection techniques. Possibly related epidemiological variables were also analyzed.

In red foxes in Galicia, cardiopulmonary parasite infection prevalences were 60.7% (210/346) overall, and 36.9% (128/346) for *Angiostrongylus vasorum*, 29.5% (102/346) for *Crenosoma vulpis* and 15.9% (55/346) for *Eucoleus aerophilus* (Table 1). The most common coinfection involved *A. vasorum* and *C. vulpis* in 13.3% (28/210) of animals testing positive for the parasites (Table 2). A significant relationship ($p = 0.03$) was observed between infection by *E. aerophilus* and sex, this infection being more prevalent in males. As an explanation, we propose that, as males are usually more active in their territory, they are more likely to ingest earthworms as intermediate hosts. In addition, although without significance, animals with a low body condition score (1-2/5) showed higher percentages of infection by all three nematode species.

In conclusion, the high burden of *Angiostrongylus* detected highlights the role of the red fox in the maintenance not only of this parasitosis but also of other potentially zoonotic diseases (e.g., *E. aerophilus*). These findings identify a need for further work designed to assess risks of cardiopulmonary parasite infections in dogs and/or humans and establish prevention measures from a “One Health” approach.

References:

1. Segovia JM, Torres J, Miquel J. Helminth parasites of the red fox (*Vulpes vulpes* L., 1758) in the Iberian Peninsula: an ecological study. :13.
2. Martínez-Rondán FJ, Ruiz de Ybáñez MR, López-Beceiro AM, Fidalgo LE, Berriatua E, Lahat L, et al. Cardiopulmonary nematode infections in wild canids: Does the key lie on host-prey-parasite evolution? Res Vet Sci. octubre de 2019;126:51-8.
3. Gerrikagoitia X, Barral M, Juste RA. *Angiostrongylus* species in wild carnivores in the Iberian Peninsula. Vet Parasitol. noviembre de 2010;174(1-2):175-80.

Table 1. Cardiopulmonary parasites quantified in the lungs of hunted red foxes

Parasite	% Prevalence	Nematode burden range/fox		Maximum nematode burden/fox
		Females	Males	
<i>A. vasorum</i>	36.9% (128/346)	1-40	1-12	51
<i>C. vulpis</i>	29.5% (102/346)	1-83	1-36	119
<i>E. aerophilus</i>	15.9% (55/346)	1-30	1-7	37





Table 2. Coinfection data recorded for cardiopulmonary parasites detected in red foxes

Detected parasites			% Coinfection (n/ positive animals)	% Coinfection (n/total animals)
<i>A. vasorum</i>	<i>C. Vulpis</i>	<i>E. aerophilus</i>		
X	X	X	5.7% (12/210)	3.4% (12/346)
X	X	-	13.3% (28/210)	8.0% (28/346)
X	-	X	6.6% (14/210)	4.0% (14/346)
-	X	X	5.7% (12/210)	3.4% (12/346)





P-2. COMPREHENSIVE MAP OF CANINE ANGIOSTRONGYLOSIS IN DOGS IN SPAIN

Carretón, E.¹, Morchón, R.^{1,2}, García Rodríguez, S. N.¹, Rodríguez Escolar, I.², Matos, J. I.¹, Costa-Rodríguez, N.¹, Montoya-Alonso, J.A.¹

¹Internal Medicine, Faculty of Veterinary Medicine, Research Institute of Biomedical and Health Sciences (IUIBS), University of Las Palmas de Gran Canaria, Las Palmas de Gran Canaria, Spain.

²Zoonotic Infections and One Health GIR, Laboratory of Parasitology, Faculty of Pharmacy, University of Salamanca, Campus Miguel Unamuno, Salamanca, Spain, rmorgar@usal.es

Keywords: *Angiostrongylus vasorum*; Spain; Europe; Epidemiology; Dogs; Provinces; Autonomous communities; Animal diseases

Canine angiostrongylosis is an emerging disease caused by *Angiostrongylus vasorum*, that mainly affects wild carnivores and dogs. In Spain, there are studies reporting infections in foxes, wolves, and badgers in different regions of the country. However, there are hardly any publications on the prevalence in dogs. The aim of this study was to complete and update the epidemiologic map of *A. vasorum* in dogs in Spain. A total of 5619 canine blood samples from all autonomous cities and provinces of Spain were collected and tested for the presence of *A. vasorum* circulating antigens. The overall prevalence of canine angiostrongylosis in Spain was 1.39%. No significant differences were found by sex or age but significant differences between outdoor and indoor/outdoor dogs were found. High prevalences were also observed in the northern third of the country, where the oceanic climate prevails, being humid, rainy and with abundant vegetation, that favours the proliferation of the intermediate hosts. The results suggest that canine angiostrongylosis is heterogeneously present in a large part of the territory, demonstrating its expansion throughout the country and, therefore, awareness and prevention campaigns for this disease should be promoted.

References

1. Morchón R, Carretón E, González-Miguel J, Mellado-Hernández I. Heartworm disease (*Dirofilaria immitis*) and their vectors in Europe – new distribution trends. *Front Physiol.* 2012; 3:196.
2. Morgan E.R, Modry D, Paredes-Esquivel C, Foronda P, Traversa D. Angiostrongylosis in Animals and Humans in Europe. *Pathogens.* 2021; 10(10), 1236.
3. Morchón R, Montoya-Alonso J. A, Sánchez-Agudo JA, de Vicente-Bengochea, J, Murcia-Martínez, X, Carretón E. *Angiostrongylus vasorum* in Domestic Dogs in Castilla y León, Iberian Peninsula, Spain. *Animals.* 2021; 11(6), 1513.
4. Carretón E, Morchón R, Falcón-Cordón Y, Matos J, Costa-Rodríguez N, Montoya-Alonso JA. First epidemiological survey of *Angiostrongylus vasorum* in domestic dogs from Spain. *Parasit. Vectors.* 2020; 13, 306.
5. Álvarez F, Iglesias R, Bos J, Rey J, San Martín Durán, M.L. Lung and hearth nematodes in some Spanish mammals. *Wiad. Parazytol.* 1991; 37, 481–490.
6. Liu J, Schnyder M, Willeesen JL, Potter A, Chandrashekar, R. Performance of the Angio Detect™ in-clinic test kit for detection of *Angiostrongylus vasorum* infection in dog samples from Europe. *Vet. Parasitol. Reg. Stud. Reports.* 2017; 7, 45-47.





P-3. STUDY OF ANGIOGENIC PROCESS IN AN IN-VIVO MODEL OF ENDOTHELIAL CELLS STIMULATED WITH ANTIGENS OF *DIROFILARIA REPENS* ADULTS WORMS

Pérez Rodríguez, P.¹, Cardona-Machado, C. D.¹, Alarcón-Torrecillas, C.², Pericacho, M.², Carretón, E.³, Montoya-Alonso, J.A.³, Rodríguez-Escolar, I.¹, Morchón, R.¹

¹Zoonotic diseases and One Health group, Laboratory of Parasitology, Faculty of Pharmacy, University of Salamanca, 37007, Salamanca, Spain. rmorgar@usal.es

²Department of Physiology and Pharmacology, Biomedical Research Institute of Salamanca (IBSAL), University of Salamanca, Salamanca, Spain.

³Internal Medicine, Faculty of Veterinary Medicine, Research Institute of Biomedical and Health Sciences (IUIBS), University of Las Palmas de Gran Canaria, Las Palmas de Gran Canaria, Spain.

Keywords: HUVEC, *Dirofilaria repens*, endothelial cells, angiogenesis.

Subcutaneous dirofilariasis, caused by *Dirofilaria repens*, is a vector-borne zoonotic disease that mainly affects canids and humans, causing subcutaneous nodules in many cases. The ability of *D. repens* to survive in the host indicates that it has developed long-term mechanisms to ensure its permanence in the host. Angiogenesis is a process in which new vessels are formed from pre-existing vessels following a hypoxic stimulus and subsequent production of vascular endothelial growth factor (VEGF). There are no studies analysing the angiogenic character of *D. repens* but there are studies on other nematodes such as *Trichinella spiralis*, in which the larvae initiate angiogenesis and attract a set of highly permeable blood vessels to the surface of their collagenous capsule present in the musculature for nutrient acquisition and waste elimination, thus maintaining a long-term host-parasite relationship. The aim was to analyze the capacity of *D. repens* antigens to modify the expression of angiogenic factors and other cellular processes in an "in vitro" model of human endothelial cells (HUVECs). HUVECs were treated with 1 ug/ml of somatic antigen of *D. repens* adult worms (DrSA), VEGF and DrSA+VEGF. Non-stimulated cells were used as controls in the same conditions. Angiogenic factors (VEGF-A, VEGFR1, VEGFR2, m- and s-Endoglin) concentration were measured using a commercial ELISA. Proliferation was analyzed by determining the number of cells by staining nuclei with MTT. Cell migration was assessed by quantifying the percentage of wound closure in the healing assay. The capacity of pseudocapillary formation was evaluated by analysing endothelial cell tube formation, the cells and intercellular junctions, and the morphological changes on Matrigel® cell cultures. The effect of DrSA+VEGF produced a significant increase in mEndoglin and VEGFR2 (proangiogenic) ($p<0.005$), increase in pseudocapillary formation ($p<0.001$), in cell migration ($p<0.001$) and in cell proliferation ($p<0.005$) compared to the other stimuli and control cells in HUVECs. *Dirofilaria repens* somatic antigen in the presence of VEGF acts as a proangiogenic stimulant in the angiogenic process (formation of new vessels) by stimulating proangiogenic molecules, as well as cell migration and proliferation and the formation of pseudocapillaries in HUVECs as a means of survival. Further studies on the angiogenic process related to *D. repens* infections in humans are needed to analyse and understand all its pathways.

References

1. Morchón R, Carretón E, González-Miguel J, Mellado-Hernández. I. Heartworm disease (*Dirofilaria immitis*) and their vectors in Europe – new distribution trends. *Front Physiol.* 2012; 3:196.
2. Ock MS, Cha HJ, Choi YH. Verifiable hypotheses for thymosin β 4-dependent and -independent angiogenic induction of *Trichinella spiralis*-triggered nurse cell formation. *Int J Mol Sci.* 2013; 14(12), 23492–23498.
3. Zueva T, Morchón R, Carretón E, Montoya-Alonso JA, Santana A, Bagues Castelló, MD, Mas-Coma S, Rodríguez-Barbero A, Simón F. Angiogenic response in an in vitro model of dog microvascular endothelial cells stimulated with antigenic extracts from *Dirofilaria immitis* adult worms. *Parasites Vectors,* 2019; 12(1), 315.





P-4. WOLBACHIA AS AN ANTIANGIOGENIC COMPONENT IN *DIROFILARIA* spp. INFECTIONS.

Cardona-Machado, C. D.¹, Pérez Rodríguez, P.¹, Alarcón-Torrecillas, C.², Pericacho, M.², Carretón, E.³, Montoya-Alonso, J.A.³, Rodríguez-Escolar, I.¹, Morchón, R.¹

¹Zoonotic diseases and One Health group, Laboratory of Parasitology, Faculty of Pharmacy, University of Salamanca, 37007, Salamanca, Spain. rmorgar@usal.es

²Department of Physiology and Pharmacology, Biomedical Research Institute of Salamanca (IBSAL), University of Salamanca, Salamanca, Spain.

³Internal Medicine, Faculty of Veterinary Medicine, Research Institute of Biomedical and Health Sciences (UIBS), University of Las Palmas de Gran Canaria, Las Palmas de Gran Canaria, Spain.

Keywords: HUVEC, *Wolbachia*, endothelial cells, angiogenesis, VEGF

Wolbachia is an endosymbiont bacterium that is present in all larval forms of the genus *Dirofilaria* spp. It is a very important component in the pathogenesis of dirofilariasis as it is involved in moulting and embryogenesis, as well as in the immune and inflammatory response of the disease. In human endothelial cells, *Wolbachia* spp. were found to have a primarily chemotactic effect by predominantly stimulating 5-lipoxygenase (5-LO) and leukotriene B4 (LTB4), as well as stimulating cell adhesion proteins such as VCA-1 and E-cadherin, with no effect on cell migration and proliferation. Angiogenesis is a process of formation of new blood vessels from pre-existing vessels. Zueva et al. (2019), in an in vitro model using dog microvascular endothelial cells, observed an anti-angiogenic effect of *Wolbachia* spp. by reducing the expression of mEndoglin (proangiogenic) and increasing the expression of sEndoglin (anti-angiogenic). The aim of this study was to investigate the anti-angiogenic effect of *Wolbachia* in an "in vitro" model of human endothelial endothelial cells (HUVECs). HUVECs were treated with 1 ug/ml of recombinant *Wolbachia* surface protein (rWSP), VEGF and rWSP+VEGF. Non-stimulated cells and stimulated cells with VEGF were used as controls in the same conditions. Angiogenic factors (VEGF-A, VEGFR1, VEGFR2, m- and s-Endoglin) concentration were measured using a commercial ELISA. Proliferation was analyzed by determining the number of cells by staining nuclei with MTT. Cell migration was assessed by quantifying the percentage of wound closure in the healing assay. The capacity of pseudocapillary formation was evaluated analyzing endothelial cell tube formation, the cells and intercellular junctions, and the morphological changes on Matrigel® cell cultures stimulated with rWSP for seven hours. The results showed that rWSP and VEGF did not produce any cytotoxic effect. The effect of rWSP+VEGF produced a significant increase in VEGF (inicio del proceso angiogénico), y VEGFR1 y mEndoglin (antiangiogenic) ($p < 0.005$), sin alterar los procesos de cell migration and proliferation compared to the other stimuli and control cells in HUVECs. The presence of *Wolbachia* in the presence of VEGF has an antiangiogenic effect in our model, corroborating previous studies, without altering structural processes. Further studies are needed to fully understand the mechanisms by which the parasite regulates in its favour. and to see whether angiogenesis is a central mechanism in the survival and/or vascular pathology of cardiopulmonary dirofilariosis.

References

1. Morchón R, Carretón E, González-Miguel J, Mellado-Hernández. I. Heartworm disease (*Dirofilaria immitis*) and their vectors in Europe – new distribution trends. *Front Physiol.* 2012; 3:196.
2. Zueva T, Morchón R, Carretón E, Montoya-Alonso JA, Santana A, Bargues Castelló, MD, Mas-Coma S, Rodríguez-Barbero A, Simón F. Angiogenic response in an in vitro model of dog microvascular endothelial cells stimulated with antigenic extracts from *Dirofilaria immitis* adult worms. *Parasites Vectors*, 2019; 12(1), 315.
3. Zueva T, Morchón R, Carretón E, Ollauri-Ibáñez C, Pericacho M, Rodríguez-Barbero A, Simón F. Angiogenesis in cardiopulmonary dirofilariosis: does the *Wolbachia* surface protein have a pro- or anti-angiogenic effect? *J Helminthol.* 2020; 94:e162.





P-5. MICROFILAREMIC *DIROFILARIA REPENS* INFECTION IN A SERBIAN PATIENT

Gabrielli, S.¹, Randjelovic, M.², Trichei, S.¹, Zdravkovic, D.², Otasevic, S.²

¹Department of Public Health and Infectious diseases, Sapienza University of Rome, Rome, Italy.
simona.gabrielli@uniroma1.it

²University of Nis, Medical faculty, Nis, Serbia.

Keywords: *Dirofilaria repens*; microfilariae; humans; Serbia.

Dirofilaria repens is a vector-borne filaroid helminth of carnivorous animals, primarily domesticated dogs. Humans are considered to be accidental hosts in which the parasite rarely reach sexual maturity but induce local inflammation, mainly in subcutaneous and ocular tissues. For this reason, humans were considered to be dead-end hosts for these helminths. In rare cases, *D. repens* can avoid the host's defense mechanisms and reach sexual maturity. In the literature, there are currently 10 case reports of human *D. repens* microfilaremia (Kludkowska *et al.*, 2018). We report a clinical case of microfilaremic dirofilariosis due to *D. repens* observed in a 43 years-old officer of the Serbian army presented a first swelling the size of a walnut and accompanied by itching inside the thigh. He was promptly treated with antibiotics in the military camp on the Danube-Tisa-Danube canal, near Vršac. After 2 months, he was referred to the Infectious disease department of the Niš Military Hospital, where a walnut-sized swelling was noted on the inner thigh. Every two to three days, the swelling migrated towards the back of the thigh. Ultrasound detected a change in the size of 13.5x8 mm. Biochemical analyzes and blood count were normal, including eosinophil level. A month later, surgical intervention was performed in the Military Hospital. According to the patient, part of the worm protruded from the removed tumor. The sampled material was brought to the Institute of Public Health, Niš, where a diagnosis of *Dirofilaria repens*-like species was performed based on the morphological characteristics of the worm. Modified Knott's test performed on 50 mL of EDTA blood, revealed the presence of 2 microfilaria/mL morphologically corresponded to *D. repens* in 3/50 preparations. Serological test also resulted positive evidenced anti-*Dirofilaria* IgG. Two months after the *D. repens* diagnosis, the patient was monitored, showing an average eosinophil count and no further microfilariae in the peripheral blood smears.

We report a new case of *D. repens* microfilaremia in the circulatory system of a healthy male patient. *D. repens* infection was finally confirmed with morphological identification of microfilariae from the blood stream. It is generally considered that human hosts are unsuitable for completion of the *D. repens* life cycle. The usual findings involve the detection of a single subadult/adult worm but, on occasion, they may develop to mature adults, mate and produce microfilariae, which may even reach the bloodstream. Although the detection of *D. repens* microfilariae in the circulation indicates the likely presence of adult worms of both sexes within the human host, the definitive presence of both adult male and female helminths in human cases remains to be demonstrated. As to whether this human and other human cases could act as reservoirs of infection, this is less clear. However, the current case, together with other microfilaremic cases previously described (Pupić-Bakrač *et al.*, 2021), provides evidence to support the role for humans as definitive hosts of *D. repens*.

References

1. Kludkowska M, Pielok Ł, Frąckowiak K, Masny A, Gołąb E, Paul M. *Dirofilaria repens* infection as a cause of intensive peripheral microfilariaemia in a Polish patient: process description and cases review. *Acta Parasitol.* 2018 Sep 25;63(3):657-663.
2. Pupić-Bakrač A, Pupić-Bakrač J, Beck A, Jurković D, Polkinghorne A, Beck R. *Dirofilaria repens* microfilaremia in humans: Case description and literature review. *One Health.* 2021 Aug 12;13:100306.





P-6. COMPREHENSIVE NATIONAL SURVEY OF FELINE DIROFILARIASIS IN SPAIN

Montoya-Alonso, J.A.¹, García Rodríguez, S. N.¹, Carretón, E.^{1*}, Rodríguez Escolar, I.², Costa-Rodríguez, N.¹, Matos, J. I.¹, Morchón, R.^{1,2}

¹Internal Medicine, Faculty of Veterinary Medicine, Research Institute of Biomedical and Health Sciences (IUIBS), University of Las Palmas de Gran Canaria, Las Palmas de Gran Canaria, Spain, elena.carreton@ulpgc.es

²Zoonotic Infections and One Health GIR, Laboratory of Parasitology, Faculty of Pharmacy, University of Salamanca, Campus Miguel Unamuno, Salamanca, Spain

Keywords: *Dirofilaria immitis*, epidemiology, seroprevalence, heartworm, dirofilariosis, cats, Spain

Heartworm infection caused by *Dirofilaria immitis* is a well-known vector-borne disease in the canine population. Its distribution is cosmopolitan, with reports found in any part of the world where the disease has been investigated in any of its hosts. Spain is considered an endemic country and there are several studies in canine hosts but not in domestic cats. The objective was to analyze the exposure to *D. immitis* throughout Spain to complete the epidemiological map in the feline species. For this, 6,588 feline serum samples were analyzed for the presence of *D. immitis* antigens and antibodies against *D. immitis* and *Wolbachia*. The results were analyzed according to sex, age, breed, habitat, origin (owned or shelter cats), presence of clinical signs, use of preventive, location and climatology. The results showed a prevalence of 0.5% and a seroprevalence of 9.4%. The highest antibody seroprevalences were reported in the Canary Islands and the Balearic Islands (19.2 and 16%, respectively), as well as in the autonomous communities located on the Mediterranean coast (9.2–11.2%). Seropositive cats were found in both indoor and outdoor cats, and from 6 months of age. Furthermore, only 5.8% of cats received regular prophylactic treatment. The results show that feline dirofilariosis is widely distributed throughout the national territory and corroborate that, where infected dogs are present, there are cats exposed to the parasite. It is necessary to implement efficient awareness and prophylaxis measures to control the incidence and expansion of feline heartworm in Spain.

References

1. Morchón R, Carretón E, González-Miguel J, Mellado-Hernández. I. Heartworm disease (*Dirofilaria immitis*) and their vectors in Europe – new distribution trends. *Front Physiol.* 2012; 3:196.
2. Montoya-Alonso JA, Carretón E, Corbera JA, Juste MC, Mellado I, Morchón R, Simón F. Current prevalence of *Dirofilaria immitis* in dogs, cats and humans from the island of Gran Canaria, Spain. *Vet Parasitol.* 2011; 176:291–294.
3. Montoya-Alonso JA, Carretón E, García-Guasch L, Expósito J, Armario B, Morchón R, Simón F. First epidemiological report of feline heartworm infection in the Barcelona metropolitan area (Spain). *Parasit Vectors.* 2014; 7:506.
4. Montoya-Alonso JA, Carretón E, Morchón R, Silveira-Viera L, Falcón Y, Simón F. The impact of the climate on the epidemiology of *Dirofilaria immitis* in the pet population of the Canary Islands. *Vet Parasitol.* (2016) 216:66–71.
5. Montoya-Alonso JA, Morchón R, Falcón-Cordón Y, Falcón-Cordón S, Simón F, Carretón E. Prevalence of heartworm in dogs and cats of Madrid, Spain. *Parasit Vectors.* (2017) 10:354.
6. Villanueva-Saz S, Giner J, Verde M, Yzuel A, González A, Lacasta D, Marteles D, Fernández A. Prevalence of microfilariae, antigen and antibodies of feline dirofilariosis infection (*Dirofilaria immitis*) in the Zaragoza metropolitan area, Spain. *Vet Parasitol Reg Stud Reports.* (2021) 23:100541.





P-7. EXPANSION OF CANINE HEARTWORM IN SPAIN.

Montoya-Alonso, J.A.¹, Morchón, R.^{1,2}, García Rodríguez, S. N.¹, Falcón-Cordón Y.¹, Costa-Rodríguez, N.¹, Matos, J. I.¹, Rodríguez Escolar, I.², Carretón, E.¹,

¹Internal Medicine, Faculty of Veterinary Medicine, Research Institute of Biomedical and Health Sciences (IUIBS), University of Las Palmas de Gran Canaria, Las Palmas de Gran Canaria, Spain.

²Zoonotic Infections and One Health GIR, Laboratory of Parasitology, Faculty of Pharmacy, University of Salamanca, Campus Miguel Unamuno, Salamanca, Spain, rmorgar@usal.es

Keywords: *Dirofilaria immitis*, epidemiology, seroprevalence, heartworm, dirofilariosis, cats, Spain Elit

Heartworm infection caused by *Dirofilaria immitis* is a well-known vector-borne disease in the canine population. Its distribution is cosmopolitan, with reports found in any part of the world where the disease has been investigated in any of its hosts. Spain is considered an endemic country and there are several studies in canine hosts but not in domestic cats. The objective was to analyze the exposure to *D. immitis* throughout Spain to complete the epidemiological map in the feline species. For this, 6,588 feline serum samples were analyzed for the presence of *D. immitis* antigens and antibodies against *D. immitis* and *Wolbachia*. The results were analyzed according to sex, age, breed, habitat, origin (owned or shelter cats), presence of clinical signs, use of preventive, location and climatology. The results showed a prevalence of 0.5% and a seroprevalence of 9.4%. The highest antibody seroprevalences were reported in the Canary Islands and the Balearic Islands (19.2 and 16%, respectively), as well as in the autonomous communities located on the Mediterranean coast (9.2–11.2%). Seropositive cats were found in both indoor and outdoor cats, and from 6 months of age. Furthermore, only 5.8% of cats received regular prophylactic treatment. The results show that feline dirofilariosis is widely distributed throughout the national territory and corroborate that, where infected dogs are present, there are cats exposed to the parasite. It is necessary to implement efficient awareness and prophylaxis measures to control the incidence and expansion of feline heartworm in Spain.

References

1. Montoya-Alonso, J. A., Morchón, R., Costa-Rodríguez, N., Matos, J. I., Falcón-Cordón, Y., & Carretón, E. (2020). Current Distribution of Selected Vector-Borne Diseases in Dogs in Spain. *Frontiers in Veterinary Science*, 7, 564429.
2. Morchón R, Carretón E, González-Miguel J, Mellado-Hernández. I. Heartworm disease (*Dirofilaria immitis*) and their vectors in Europe – new distribution trends. *Front Physiol*. 2012; 3:196.
3. Pérez Pérez, P., Rodríguez-Escolar, I., Carretón, E., Sánchez Agudo, J. Á., Lorenzo-Morales, J., Montoya-Alonso, J. A., & Morchón, R. (2021). Serological Survey of Canine Vector-Borne Infections in North-Center Spain. *Frontiers in Veterinary Science*, 8, 784331.





P-8. ANGIOSTRONGYLUS CHABAUDI NATURAL INFECTION IN WILD CAUGHT GASTROPODS

Dimzas, D.¹, Di Cesare, A.², Morelli, S.², Iorio, R.², Backeljau, T.^{3,4}, Vanderheyden, A.³, Lombal, A.³, De Meyer, M.⁵, Meganck, K.⁵, Smits, N.⁵, Kassari, N.⁶, Traversa, D.², Diakou, A.^{1*}

¹ School of Veterinary Medicine, Faculty of Health Sciences, Aristotle University of Thessaloniki, 54124 Thessaloniki, Greece, diakou@vet.auth.gr

² Faculty of Veterinary Medicine, Teaching Veterinary Hospital, 64100 Teramo, Italy

³ Royal Belgian Institute of Natural Sciences (BopCo), 1000 Brussels, Belgium

⁴ Evolutionary Ecology Group, Department of Biology, University of Antwerp, 2610 Antwerp, Belgium

⁵ Royal Museum for Central Africa (BopCo), 3080 Tervuren, Belgium

⁶ Department of Biology, University of Crete, 70013 Irakleio, Greece

Keywords: *Angiostrongylus chabaudi*, Slugs, Snails, Domestic cat, Wildcat

Angiostrongylus chabaudi is a metastrongyloid nematode of the pulmonary arteries and the right chambers of the heart of wildcats (*Felis silvestris*). Rare cases of domestic cat (*Felis catus*) infection have also been reported (1). *Angiostrongylus chabaudi* has an indirect life cycle with terrestrial gastropods acting as intermediate hosts. Although experimental infection of the snail *Cornu aspersum* with *A. chabaudi* was successful (2), information about naturally infected gastropods that may participate to the life cycle of the parasite are scant (3). The present study reports the presence of *A. chabaudi* first, second and third stage larvae in wild-caught gastropods from habitats of wildcats and domestic cats in Greece.

In this study 1212 terrestrial mollusks were collected by hand from 20 geographical regions of Greece, including urban, semi-urban, rural, and wild type environments. The gastropods were identified by morphology and DNA barcoding and processed by artificial digestion for nematode detection. Identification of the retrieved metastrongyloid larvae to the species level was performed based on morphological/morphometric characteristics and confirmed by molecular methods.

Angiostrongylus chabaudi was found in 5 slugs of the species *Limax conemenosi* O. Boettger, 1882 and in 16 snails of the species *Helix lucorum* Linnaeus, 1758 (n=6), *Helix philibinensis* Rossmässler, 1839 (n=1), *Eobania vermiculata* (O.F. Müller, 1774) (n=7), *Caucasotachea vindobonensis* (C. Pfeiffer, 1828) (n=1), and *Zebrina detrita* (O.F. Müller, 1774) (n=1). Infected gastropods were collected from semi-urban and wild type environments, in 5 locations of Northern Greece, where wildcat populations are widespread.

The present study reports 3 new snail species, naturally infected with *A. chabaudi*, i.e. *H. philibinensis*, *C. vindobonensis*, and *Z. detrita*. Even though to date, feline angiostrongylosis is limited to wildcats and does not represent a threat for domestic cats, it cannot be excluded that epizootiological drivers, such as climatic change, biology and distribution of the gastropod-intermediate hosts, and global trade that can introduce infected gastropods in new areas, may promote further expansion of the parasite to naïve regions and favor a spillover to domestic cats, particularly in areas where these two felid species live in sympatry.

References

1. Morgan ER, Modry D, Paredes-Esquivel C, Foronda P, Traversa D. Angiostrongylosis in animals and humans in Europe. *Pathogens*. 2021 Sep;10(10):1236.
2. Colella V, Cavalera MA, Deak G, Tarallo VD, Gherman CM, Mihalca AD, Otranto D. Larval development of *Angiostrongylus chabaudi*, the causative agent of feline angiostrongylosis, in the snail *Cornu aspersum*. *Parasitology*. 2017 Aug;144(14):1922–1930.
3. Dimzas D, Morelli S, Traversa D, Di Cesare A, Van Bourgonie YR, Breugelmans K, Backeljau T, di Regalbono AF, Diakou A. Intermediate gastropod hosts of major feline cardiopulmonary nematodes in an area of wildcat and domestic cat sympatry in Greece. *Parasit Vectors*. 2020 Jul;13(1): 345.





P-9. DOES COMBINED TREATMENT FOR DIROFILARIOSIS INFLUENCE THE EXPRESSION OF GENES CODING FOR ABC TRANSPORTERS AND *WOLBACHIA* LOAD IN *DIROFILARIA IMMITIS*? RESULTS FROM AN *IN VITRO* EXPERIMENT ON ADULT WORMS

Vismarra, A.¹, Genchi, M.¹, Semeraro, M.¹, Lucchetti, C.², Bazzocchi, C.³, Cafiso, A.³, Kramer, L.¹

1. Dipartimento di Scienze Medico-Veterinarie, Università di Parma, via del Taglio, 10, 43126, Parma, Italy, alice.vismarra@unipr.it
2. Istituto Zooprofilattico Sperimentale della Lombardia e dell'Emilia Romagna, Via Pitagora, 2, 42124 Reggio Emilia, Italy.
3. Dipartimento di Medicina Veterinaria e Produzioni Animali, Università di Milano, Via dell'Università, 6, 26900, Lodi, Italy.

Keywords: *Dirofilaria immitis*, ABC transporters gene, combined treatment, *Wolbachia*

Macrocyclic lactones (MLs) are widely used antihelminthic drugs. Due to their marked larvicidal activity, their use in the mainstay of *Dirofilaria immitis* prevention in dogs. They have been also shown to eliminate adult parasites after long-term administration, with a so called “slow-kill” effect¹. In addition, recent studies have established that a combination of doxycycline, targeting the endosymbiont *Wolbachia*, with MLs has superior adulticide effects when compared to MLs alone². The apparent synergism between doxycycline/MLs may be due to interaction with drug efflux transport proteins. The aim of the study was to evaluate gene expression of several transport proteins in *D. immitis*.

Adult parasites were treated *in vitro* either with doxycycline, ivermectin, moxidectin, doxycycline + ivermectin, doxycycline + moxidectin in RPMI medium for 12 h at 37°C, 5% CO₂. Each treatment was performed in triplicates for both sexes. RNA and DNA were isolated for subsequent analyses (quantitative Real-time PCR for relative gene expression and the absolute quantification of *Wolbachia*).

Quantitative PCR analysis showed a sex-dependent response to treatments. In female worms, *Dim-pgp-10* and *Dim-haf-5* were upregulated compared to controls with doxycycline alone and when combined with ivermectin. In males, moxidectin administered alone induced a slight increase in *Dim-pgp-10*, *Dim-pgp-11*, *Dim-haf-1* and *Di-avr-14*, while ivermectin in combination with doxycycline produced significant upregulation of the ML receptor *Di-avr-14*.

These results suggest possible synergism between the two drug classes and different susceptibility of males vs. females to adulticide effects.

References

1. McCall JW, 2005. The safety-net story about macrocyclic lactone heartworm preventives: a review, an update, and recommendations. *Vet. Parasitol.* 133(2-3):197-206.
2. Bazzocchi C et al., 2008. Combined ivermectin and doxycycline treatment has microfilaricidal and adulticidal activity against *Dirofilaria immitis* in experimentally infected dogs. *Int. J. Parasitol.* 38(12):1401-1410.





P-10. MAPPING THE HEARTWORM INFECTION IN THE HYPERENDEMIC ISLAND OF GRAN CANARIA (2018-2020).

Montoya-Alonso, J.A.¹, García-Rodríguez, S.N.¹, Matos, J.I.¹, Costa-Rodríguez, N.¹, Falcón-Cordón, Y.¹, Morchón, R.^{1,2}, Carretón, E.¹.

¹Internal Medicine, Faculty of Veterinary Medicine, Research Institute of Biomedical and Health Sciences (IUIBS), University of Las Palmas de Gran Canaria, Las Palmas de Gran Canaria, Spain, saranierves.garcia@ulpgc.es

²Zoonotic Infections and One Health GIR, Laboratory of Parasitology, Faculty of Pharmacy, University of Salamanca, Campus Miguel Unamuno, Salamanca, Spain,

Keywords: Heartworm disease, *Dirofilaria immitis*, Gran Canaria, Epidemiology, Animal disease.

Heartworm disease is caused by *Dirofilaria immitis*, which is a nematode that is transmitted through the bite of hematophagous mosquitoes. Dogs and cats are the most affected reservoirs; humans can also be infected, being considered a zoonotic disease. The first study of the prevalence of *D. immitis* that was carried out on the island of Gran Canaria was in 1994, showing a prevalence of 67.02% in the canine population studied. Over time, these data have been decreasing. However, it is still considered a hyperendemic island. This study shows unpublished data on the prevalence of *D. immitis* in dogs, cats and inhabitants of the island of Gran Canaria, from 2018 to 2020. A total of 969 dogs, 707 cats, and 411 humans were analyzed for detection of antigens (dogs) or antibodies (cats and humans) against *D. immitis*, over a 3-year period (2018-2020) in Gran Canaria. Data on age, sex, habitat and geographic climate were taken into account. There were no significant differences between age or sex. Those dogs and cats with access to the outside presented greater exposure to the parasite than those that lived exclusively indoors. It was observed that the prevalences in dogs and cats were higher in those areas of the island with a temperate and cold climate (TC), followed by temperate and mild climate zone (TM), and later dry and steparic climate zone (DS). Dry and desert climate zone (DD) presented the lowest prevalence in all the years studied. In the case of humans, the prevalences according to the climate varied in the different years, but the TC and TM climates were always higher. Meanwhile, those inhabitants of DS climates always presented the lowest prevalences. Likewise, there was no marked variation in the prevalences of the last three years in the three species studied. The prevalences in dogs ranged from 16.09% to 15.71%, ending with 15.81%. In the case of cats, they went from 17.19% to 17.91%, ending with 17.20% in 2020. Finally, the prevalence in humans started at 10.43% in 2018, going through 9.2% in 2019, until reaching 8.27% in 2020. These results show stable prevalences in recent years thanks to the implementation of control and prophylactic measures in Gran Canaria. However, it is important to improve hygienic-sanitary conditions and increase knowledge of the disease among the inhabitants of the island to reduce the number of untreated reservoirs, which are an impediment for the data to continue to decrease. Furthermore, these results also show the zoonotic importance of this disease, and therefore, reinforce the need for control measures.

This study was partially supported by ELANCO SPAIN S.L (CN-240/030/159).

References

1. Montoya, J.A., Morales, M., Ferrer, O., Molina, J.M., & Corbera, J.A. The prevalence of *Dirofilaria immitis* in Gran Canaria, Canary Islands, Spain (1994-1996). *Veterinary Parasitology* 2018; 75:221-226.
2. Montoya-Alonso, J.A., Carretón, E., Morchón, R., Silveira-Viera, L., Falcón, Y., & Simón, F. The impact of the climate on the epidemiology of *Dirofilaria immitis* in the pet population of the Canary Islands. *Veterinary Parasitology* 2016; 216:66-71.





P-11. TRICUSPID REGURGITATION VELOCITY/PULMONARY ARTERY FLOW VELOCITY TIME INTEGRAL MEASURED BY ECHOCARDIOGRAPHY IN CANINE HEARTWORM DISEASE

Matos, J.I.¹, García-Rodríguez, S.N.¹, Costa-Rodríguez, N.¹, Falcón-Cordón, Y.¹, Carretón, E.¹, Montoya-Alonso, J.A.¹

¹Internal Medicine, Faculty of Veterinary Medicine, Research Institute of Biomedical and Health Sciences (IUIBS), University of Las Palmas de Gran Canaria, Las Palmas de Gran Canaria, Spain, Jorge.matos@ulpgc.es

Keywords: Heartworm, *Dirofilaria immitis*, Echocardiography, Pulmonary hypertension, Animal disease.

Pulmonary hypertension (PH) is a hemodynamic condition in which the pressure of the pulmonary arterial vasculature is elevated. It is a complex syndrome that usually occurs in dogs parasitized by *Dirofilaria immitis*. Damage to the pulmonary vasculature causes progressive and permanent changes in parasitized animals. Serious cardiorespiratory signs appear and require chronic treatment. The use of echocardiographic measurements for the estimation of PH in heartworm disease is essential, and new methods have to be implemented in order to improve the diagnosis and prognosis of affected dogs. The objective of this research was to evaluate the Tricuspid Regurgitation Velocity/Pulmonary Artery Flow Velocity Time Integral (TRV/VTI_{pa}) measurement in dogs parasitized by *D. immitis* to determine its efficacy in estimating the presence of PH.

In this study, 49 animals were selected between September 2021 and June 2022. A complete record was kept for each animal, including identification (age, sex, breed, and weight), body score condition (BSC), presence of respiratory symptoms and signs of congestive right heart failure (RCHF). 57,14% of the animals were diagnosed by a *D. immitis* circulating antigen test using a commercial diffusion immunochromatography kit, the rest of the animals (42,86%) were healthy control animals. The dogs were conscious, monitored and without the use of sedation or anesthesia throughout the echography exam. The absence or presence of PH was determined using the right pulmonary artery distensibility index (RPADi<29.5%). Pulmonary artery flow velocity time integral (VTI_{pa}) and tricuspid regurgitation velocity (TRV) were obtained with spectral wave Doppler in the right and left parasternal views, following previously published and validated protocols.

The study population were allocated into 3 groups depending on the presence of the disease and PH. The clinical data of the groups are presented in Table 1. The RPDi determined the presence of PH in 53,57% of the parasitized animals. There were no significant differences in body weight, BSC, and age among the dogs in the three groups. Significant results were observed in the presence of respiratory symptoms and signs of RCHF when the animals suffered from PH. All VTI_{pa} measurements were adjusted by BSA. There were significant differences in VTI_{pa}/BSA and (TRV/VTI_{pa})/BSA between groups (P<0,01), with higher values in the group of animals suffering from PH (0,92± 0,25 Vs 1,83±0,34).

In conclusion, it is suggested that TRV/VTI_{pa} could be included as a simple and non-invasive parameter to determine the presence of PH through routine echocardiographic examination in dogs suffering from heartworm disease. New studies are indicated to standardize protocols and obtain exact reference values.

The presented study was supported by own funds from the Veterinary Medicine Service FULP/ULPGC (SD-240/030/0026).





P-12. TOMOGRAPHIC STUDY OF PULMONARY LESIONS OBSERVED IN CATS NATURALLY INFECTED BY *DIROFILARIA IMMITIS*

García-Rodríguez, S.N.¹, Matos, J.I.¹, Costa-Rodríguez, N.¹, Falcón-Cordón, Y.¹, Carretón, E.¹, Montoya-Alonso, J.A.¹

¹Internal Medicine, Faculty of Veterinary Medicine, Research Institute of Biomedical and Health Sciences (IUIBS), University of Las Palmas de Gran Canaria, Las Palmas de Gran Canaria, Spain, saraniieves.garcia@ulpgc.es

Keywords: Heartworm disease, *Dirofilaria immitis*, Cat, Computed Tomography, Animal disease.

Cardiopulmonary disorders caused by *Dirofilaria immitis* in the feline species have increased their relevance in recent years due to the clinical importance of this disease in endemic areas. The use of diagnostic techniques has been based mainly on the use of radiographs and serological tests. However, the recent use of Computed Tomography (CT) is proposed as an accurate and highly sensitive method to detect cardiorespiratory injuries. Despite this, few studies have been carried out in cats with the disease. The objective of this study was to assess the tomographic findings observed in cats naturally infected by immature larvae of *D. immitis* (Heartworm Associated Respiratory Disease). A total of 10 cats (3 males and 7 females) naturally infected by immature larvae of *D. immitis* were submitted CT at the Veterinary Clinical Hospital of the University of Las Palmas de Gran Canaria, between May and July 2022. Data on age, breed, sex, habitat and symptoms were collected. All owners gave their consent to perform the tests. The animals were monitored and the same anesthetic protocol was used in all cases. CT exams were obtained through 1 mm thick sections, using helical CT scanner (Toshiba Astelion, Toshiba Medical System, Madrid, Spain), whose views were visualized in the pulmonary window (W 1500, L 600). After this, the studies were evaluated using DICOM image analysis software. Pulmonary and cardiovascular inflammatory lesions caused by *D. immitis* were studied in all animals, based on the number of affected lung lobes, the degree of increased opacity, and the location of the lung region. The results showed the presence of signs of a multifocal interstitial pattern, tortuous and enlarged pulmonary arteries, with perivascular pulmonary infiltration and signs of consolidation in the cats studied. The previously described lesions were found mainly in the caudal lobes in 80% of the animals analyzed. Furthermore, the lesions were diffuse and bilateral affecting the entire pulmonary parenchyma. The lesions evaluated were mainly of a moderate nature, being present in 60% of the cats. However, a 10% of cats presented mild character and 30% of cats showed severe nature. Finally, the main distribution pattern was infiltrative multifocal in 40% of cats. The results shown demonstrate that this technique has been able to characterize thoracic lesions in all the naturally infected cats studied, being able to explain the phenomena of bronchopneumonia, thromboembolism, and pulmonary hypertension. It is proposed to continue studying the lesions observed in parasitized cats. For this, a greater number of samples and control cats are required, in addition to effective diagnostic protocols for the standardization of the method. The present study was supported by Merck Sharp and Dohme Animal Health, S.L (CN-240/030/158).

References

1. Panopoulos, I., Specchi, S., Soubasis, N., Papasteganou, A., Brellou, G., & Auriemma, E. Multidetector computed tomographic pulmonary angiography in a cat with fatal heartworm disease. *Veterinary Radiology and Ultrasound* 2017; 1-5.





P13. IMPORTANCE OF ANAMNESIS AND PHYSICAL EXAMINATION IN CANINE HEARTWORM DISEASE

Matos, J.I.¹, García-Rodríguez, S.N.¹, Costa-Rodríguez, N.¹, Falcón-Cordón, Y.¹, Carretón, E.¹, Montoya-Alonso, J.A.¹

¹Internal Medicine, Faculty of Veterinary Medicine, Research Institute of Biomedical and Health Sciences (IUIBS), University of Las Palmas de Gran Canaria, Las Palmas de Gran Canaria, Spain, Jorge.matos@ulpgc.es

Keywords: Heartworm, *Dirofilaria immitis*, Anamnesis, Physical examination, Animal diseases.

The history and physical examination are the first procedures in veterinary clinical practice. The valuable information collected is essential to determine the rest of the complementary diagnostic tests necessary for the correct management of canine heartworm disease. The objective of this study was to analyze the main findings reported in the anamnesis and physical examination of a group of canine patients infected by *Dirofilaria immitis*. A total of 192 dogs of 23 different breeds were diagnosed with heartworm through a commercial test for the detection of *D. immitis* antigens (Urano test Dirofilaria®, Urano Vet SL, Barcelona, Spain) at the University of las Palmas de Gran Canaria Veterinary Faculty, between September 2020 and July 2022. The data from the anamnesis and physical examination were collected systematically. In all cases the owners were informed to participate in the study. The information of the different variables was analyzed through statistical analysis software (BM SPSS Statistics 25.0, New York, USA). The results show 45,31% females and 54,69% males with a mean age of 8,4 years and a mean weight of 16,7 kg. 7,81% were dogs with long hair, 12,5% medium hair and 79,70 short hair. The anamnesis showed that 48,96% animals did not take deworming, 44,27% intermittently and 6,77% did take it rigorously. The most affected breed was the Podenco canario (8,33%). 25% lived outdoors, 23,44% indoors and 51,56% in a mixed environment. It was observed that 14,58% of the animals did not present any symptoms of disease. The main symptoms reported were dry and productive cough (59,75%), dyspnea (31,48%), exercise intolerance (28,12%), syncope (22,22%), hyporexia (25,96%), diarrhea (21,34%), vomiting (13,41%) and hemoglobinuria (5,49%). The progression of symptoms was chronic in 53,65%, subacute in 38,07%, and acute in 8,28%. Physical examination showed a mean heart rate of 134,5 and a respiratory rate of 38,4. The grade of body score condition more observed was 5/9. The presence of heart murmur was determined in 28,13% animals, (38,80% in the right hemithorax, 27,78% in the left hemithorax and 33,42% bilateral), with a mean intensity of III/IV and systolic characterization. 39,06% of animals were reported with pulmonary crackles, 28,65% had wheezing, 7,29% had rales, and 6,77% had stridor. The presence of abnormal respiratory pattern was determined in 34,38 % of the animals. The presence of ascites was observed in 23,44%. The average temperature was 38,17°C. Presence of white mucous membranes with CRT>2sg in 30,73% of the animals. The presence of a weak, asymmetric or synchronous femoral pulse was observed in 28,65% of the animals. The history and physical examination in the canine patient with heartworm disease show high degrees of similarity between the different clinical presentations. The cardiorespiratory findings are the main representatives in this disease and the information obtained through the owner is generally useful. Further future studies in other geographical areas and with a larger number of animals are considered necessary to standardize clinical information and devise specific protocols for the diagnosis of canine heartworm.

This study was partially supported by ELANCO SPAIN S.L (CN-240/030/159) and was funded by the Veterinary Medicine Service FULP/ULPGC SD-240/030/0026.





P-14. TWO-DIMENSIONAL ECHOCARDIOGRAPHIC MEASUREMENTS FOR DIAGNOSIS AND STAGING OF HEARTWORM DISEASE

Matos, J.I.¹, García-Rodríguez S.N.¹, Costa-Rodríguez, N.¹, Falcón-Cordón, Y.¹, Carretón, E.¹, Montoya-Alonso J.A.¹

¹Internal Medicine, Faculty of Veterinary Medicine, Research Institute of Biomedical and Health Sciences (IUIBS), University of Las Palmas de Gran Canaria, Las Palmas de Gran Canaria, Spain, Jorge.matos@ulpgc.es

Keywords: Heartworm, *Dirofilaria immitis*, Echocardiography, Pulmonary hypertension, Animal disease.

Cardiovascular changes caused by *Dirofilaria immitis* produce a succession of hemodynamic alterations that can be observed by echocardiography. Doppler methods are considered optimal for the diagnosis and staging of pulmonary hypertension (PH) and other disorders in heartworm disease, however they are considered difficult modes and sometimes impossible to quantify. The two-dimensional mode (2d) offers faster learning and greater ease of performance compared to the Doppler modes and its effectiveness has already been demonstrated in multiple canine heart diseases. The objective was to assess the usefulness of using measurements obtained by 2d echocardiographic mode in dogs suffering from heartworm.

In this study, 96 dogs were subjected to echocardiographic study without the use of sedation or anesthesia. The absence or presence of PH was determined using the right pulmonary artery distensibility index (RPADi < 29.5%). All measurements in 2d mode were adjusted for body surface area (BSA). The normalized minor (Minor RAn) and major (Major RAn) diameter of the right atrium, normalized tricuspid valve annulus diameter (TVADn), normalized major (Major RVn) and minor (Minor RVn) diameter of the right ventricle, right atrial area index (RAAi), right ventricular end-diastolic area index (RVEDAi) and right ventricular outflow tract-fractional shortening (RVOT-FS), were obtained with 2d mode in the right and left parasternal views, following previously published and validated protocols.

Through the use of RPADi, 3 groups of animals were created; 46,88% healthy animals (group A), 26,04% animals infected without PH (group B) and 27,08% animals infected with PH (group C). Presence of PH was observed in 50,98% of infected dogs. In general, the studied 2d mode measurements showed significant differences ($p < 0.05$). Higher values were reported comparing group C and the animals in groups A and B. On the other hand, no differences were shown between groups A and B.

Heartworm disease produces pressure overload alterations in the right heart chambers that, in chronic conditions, impair cardiac contractility and generate congestion and right heart failure. The results observed in the morphological alterations of the cardiac chambers, walls, and the valvular structures suggest that these can only be quantified in advanced stages of the disease. Therefore, the use of measurements in 2d mode is restricted to certain circumstances and must be supported by other echocardiographic modes. However, the easy determination of the measurements in 2d mode could be included as a simple and non-invasive method to determine the presence of PH through routine echocardiographic examination in dogs suffering from heartworm. New studies are indicated to standardize protocols and obtain exact reference values.

The presented study was supported by own funds from the Veterinary Medicine Service FULP/ULPGC (SD-240/030/0026).





P-15. HIGH PREVALENCE OF CARDIOPULMONARY WORMS DETECTED IN THE IBERIAN WOLF (*CANIS LUPUS*): A THREAT FOR WILD AND DOMESTIC CANIDS

Estévez-Sánchez, E.¹; Checa, R.¹; Montoya, A.¹; Barrera, J.P.¹; López-Beceiro, A.M.²; Fidalgo, L.E.²; Miró, G.¹.

¹Departamento de Sanidad Animal, Facultad de Veterinaria, Universidad Complutense de Madrid, Avda. Puerta de Hierro s/n, Madrid, España, efredest@ucm.es

²Departamento de Anatomía, Producción Animal y Ciencias Clínicas Veterinarias, Facultad de Veterinaria, Universidad de Santiago de Compostela, Campus Terra. Lugo, España.

Keywords: *Angiostrongylus vasorum*, *Eucoleus aerophilus*, *Crenosoma vulpis*, *Canis lupus signatus*, Northwestern Spain.

Cardiopulmonary nematodes are highly pathogenic parasites affecting domestic and wild canids. As the result of conservation programmes, the Iberian wolf (*Canis lupus signatus*) population has recently expanded, and its distribution range covers lands from where it had long disappeared. However, the exact epidemiological role of the wolf in the life cycle of zoonotic parasites causing diseases transmissible to pets and/or humans is largely unknown. This study sought to determine the diversity of cardiopulmonary nematode parasite species that affect wolves inhabiting northwestern areas of the Iberian Peninsula, and to estimate their prevalence and the relationship between these parasites and several epidemiological variables.

The study population comprised 57 Iberian wolves from Galicia (from the provinces A Coruña n=15, Lugo n=21, Ourense n=15 and Pontevedra n=6). These wolves had died of natural causes or had been killed in road accidents and were collected by official organisms of Galicia over the period 2016 to 2021. The cardiopulmonary systems we examined using techniques of dissection and cup sedimentation (Figure 1). Collected worms were then identified under a light microscope according to their morphological features and possibly related variables were analyzed through Fisher exact test at a 95% confidence interval (significance was set at $p \leq 0.05$).

Three species of nematodes were detected: *Angiostrongylus vasorum* (the “French-heartworm”) (Figure 2), *Crenosoma vulpis* and *Eucoleus aerophilus*, the latter being of zoonotic interest. Prevalences were 24.5% (14/57; 95% CI 13.3% - 35.6%) overall, and 19.3% for *A. vasorum* (11/57; 95% CI 8.8% - 29.2%), 7% for *C. vulpis* (4/57; 95% CI 0.4% - 13.6%), and 3.5% for *E. aerophilus* (2/57; CI -1.1% - 9.1%) (Table 1). A significant relationship ($p=0.002$) was found between age and the presence of *C. vulpis*, which was only found in juvenile animals. Further, a higher prevalence of *A. vasorum* and/or *C. vulpis* was observed in wolves with a lower body condition score (40% and 20%, respectively) though the difference was not significant ($p=0.221$ and $p=0.444$, respectively). Our findings indicate a high “French-heartworm” and lungworm burden in the wolf population of northern Spain and identify a need for studies designed to elucidate the epidemiological role played by the Iberian wolf and identify possible risks for veterinary and public health.

Acknowledgments: Wild Fauna Recovery Centres of Galicia; Dirección Xeral de Patrimonio Natural (Xunta de Galicia, Spain).

References

1. Martínez-Rondán FJ, Ybáñez MRR de, López-Beceiro AM, Fidalgo LE, Berriatua E, Lahat L, et al. Cardiopulmonary nematode infections in wild canids: Does the key lie on host-prey-parasite evolution? *Research in Veterinary Science*. 2019;126:51–8.
2. Segovia J, Torres J, Miquel J, Llana L, Feliu C. Helminths in the wolf, *Canis lupus*, from north-western Spain. *Journal of helminthology*. 2001;75(2):183–92.
3. Traversa D, Di Cesare A, Conboy G. Canine and feline cardiopulmonary parasitic nematodes in Europe: emerging and underestimated. *Parasites & Vectors*. 2010 Jul 23;3(1):62.





P-16. USEFULNESS OF THORACIC RADIOLOGICAL SIGNS FOR THE DIAGNOSIS AND STAGING OF SEVERITY IN DOGS WITH HEARTWORM

Martínez-Bencomo, A.¹, Falcón-Cordón, S.¹, Falcón-Cordón, Y.¹, Matos Rivero, J.I.¹, Montoya-Alonso, J.A.¹, Carretón, E.¹

¹Faculty of Veterinary Medicine, Research Institute of Biomedical and Health Sciences (IUIBS), University of Las Palmas de Gran Canaria, Arucas, 35413, Las Palmas, Spain. yaiza.falcon@ulpgc.es

Keywords: heartworm, thoracic radiology, diagnosis,

Dirofilaria immitis is a nematode that causes heartworm disease, which is a severe pathology that causes cardiopulmonary alterations in dogs. Although radiography is used routinely in the study of dogs with heartworm, there are hardly any studies that determine its objective usefulness to detect alterations caused by parasites and establish the severity of the disease. Therefore, the aim was to determine whether specific thoracic radiography findings in dogs with heartworm are associated with some clinical variables, which were: presence/severity of pulmonary hypertension (PH), parasitic burden or presence of microfilariae, as well as epidemiological variables (age and sex). Dorso-ventral and right lateral thoracic radiography projections were made in 49 heartworm-infected dogs, and the vertebral heart score (VHS), the right cranial pulmonary artery at the level of the fourth rib (PA:4R) ratio, and the diameter of the right caudal pulmonary artery at the level of the ninth rib (PA:9R) ratio were calculated. All the animals were subjected to an echocardiography examination to estimate the parasite burden and the presence of PH based on a right pulmonary artery distensibility index (RPADi). Additionally, blood samples were collected to assess the presence of microfilariae. The results showed that there were 85.7% of dogs with radiographic lung alterations (mainly vascular pattern, interstitial or bronco-interstitial pattern) and 67.3% presented anomalies of the cardiac silhouette (mainly cardiomegaly, enlargement of the right chambers and dilatation of the pulmonary trunk). The VHS was increased in 42.9% of dogs and PA:4R and PA:9R ratios were enlarged in 31.3% and 19.5%, respectively. The VHS was not useful to evaluate any of the studied epidemiological and clinical parameters but the PA:4R and PA:9R ratios were significantly increased in dogs with PH. Moreover, Pearson's correlation analysis showed a negative relation between the PA:4R and PA:9R ratios, and the RPADi. Moreover, the PA:4R and PA:9R ratios were significantly increased in dogs with high parasite burden. Similarly, older dogs presented significantly higher PA:4R and PA:9R ratios. Results showed that thoracic radiography could be a useful and complementary important tool to assess cardiopulmonary alterations in canine heartworm disease.

Clinical/epidemiological variable	Groups by variable	PA:4R ratio	PA:9R ratio
Pulmonary Hypertension (RPADi <29%) *	Presence of PH	1.16 ± 0.32	1.31 ± 0.30
	Absence of PH	0.92 ± 0.19	1.07 ± 0.19
Parasite burden *	High burden	1.13 ± 0.28	1.23 ± 0.29
	Low burden	0.88 ± 0.22	1.09 ± 0.21
Microfilariae	Presence of MF	1.04 ± 0.29	1.18 ± 0.28
	Absence of MF	0.92 ± 0.21	1.08 ± 0.16
Age *	Older dogs (6-15 years)	1.13 ± 0.22	1.24 ± 0.31
	Younger dogs (1-5 years)	0.95 ± 0.35	1.12 ± 0.21
Sex	Females	1.04 ± 0.27	1.20 ± 0.25
	Males	0.99 ± 0.30	1.11 ± 0.30

Table 1. Results of PA:4R and PA:9R ratios. (*): statistically significant differences between groups in both ratios.

References

1. Buchanan JW, Bücheler J. (1995). Vertebral scale system to measure canine heart size in radiographs. J Am Vet Med Assoc. 206:194-199.
2. Falcón-Cordón Y, Montoya-Alonso JA, Caro-Vadillo A, Matos-Rivero JI, Carretón E (2019). Persistence of pulmonary endarteritis in canine heartworm infection 10 months after the eradication of adult parasites of *Dirofilaria immitis*. Vet Parasitol. 273:1-4.
3. Kim, S., Park, H., Lee, J., Lee, Y., Choi, H. (2019). Comparison of Radiographic and Echocardiographic Features between Small and Large dogs with Heartworm Disease. J Vet Clinics. 36: 207-211.
4. Oui, H., Oh, J., Keh, S., Lee, G., Jeon, S., Kim, H., Yoon, J., Choi, J. (2015). Measurements of the pulmonary vasculature on thoracic radiographs in healthy dogs compared to dogs with mitral regurgitation. Vet Radiol Ultrasound. 56: 251-256.





5. Venco, L., Genchi, C., Colson, P.V., Kramer, L. (2003). Relative Utility of Echocardiography, Radiography, Serologic Testing and Microfilariae Counts to Predict Adult Worm Burden in Dogs Naturally Infected with Heartworms. In: Seward RL, Knight DH, editors. Recent Advances in Heartworm Disease, Symposium'01. Batavia, IL: American Heartworm Society; pp. 111–124.





**THANK YOU
FOR COMING**

